

Diagnosis and Management of Prosthetic Joint Infection: Clinical Practice Guidelines by the Infectious Diseases Society of America^a

Douglas R. Osmon,¹ Elie F. Berbari,¹ Anthony R. Berendt,² Daniel Lew,³ Werner Zimmerli,⁴ James M. Steckelberg,¹ Nalini Rao,^{5,6} Arlen Hanssen,⁷ and Walter R. Wilson¹

¹Division of Infectious Diseases, Mayo Clinic College of Medicine, Rochester, Minnesota; ²Bone Infection Unit, Nuffield Orthopaedic Centre, Oxford University Hospitals NHS Trust, United Kingdom; ³Division of Infectious Diseases, Department of Internal Medicine, University of Geneva Hospitals, ⁴Basel University Medical Clinic, Liestal, Switzerland; ⁵Division of Infectious Diseases, Department of Medicine, and ⁶Department of Orthopaedic Surgery, University of Pittsburgh School of Medicine, Pennsylvania, and ⁷Department of Orthopedics, Mayo Clinic College of Medicine, Rochester, Minnesota

These guidelines are intended for use by infectious disease specialists, orthopedists, and other healthcare professionals who care for patients with prosthetic joint infection (PJI). They include evidence-based and opinion-based recommendations for the diagnosis and management of patients with PJI treated with debridement and retention of the prosthesis, resection arthroplasty with or without subsequent staged reimplantation, 1-stage reimplantation, and amputation.

Keywords. prosthetic joint infection; PJI; surgical intervention; antimicrobial.

EXECUTIVE SUMMARY

Background

Joint replacement is a highly effective intervention that significantly improves patients' quality of life, providing symptom relief, restoration of joint function, improved mobility, and independence. Prosthetic joint infection (PJI) remains one of the most serious complications of prosthetic joint implantation. The management of PJI almost always necessitates the need for

surgical intervention and prolonged courses of intravenous or oral antimicrobial therapy [1–4]. Despite a significant amount of basic and clinical research in this field, many questions pertaining to the definition of infection as well as diagnosis and management of these infections remain unanswered. The focus of these guidelines is to provide a consensus statement that addresses the diagnosis and the medical and surgical treatment of infections involving a prosthetic joint. In many situations, the panel has made recommendations based on expert opinion, realizing that the amount of data to support a specific recommendation is limited and that there are diverse practice patterns which seem to be equally effective for a given clinical problem.

An essential component of the care of patients with PJI is strong collaboration between all involved medical and surgical specialists (eg, orthopedic surgeons, plastic surgeons, infectious disease specialists, internists). It is anticipated that consideration of these guidelines may help reduce morbidity, mortality, and the costs associated with PJI. The panel realizes that not all medical institutions will have the necessary resources to

Received 3 September 2012; accepted 5 September 2012; electronically published 6 December 2012.

^aIt is important to realize that guidelines cannot always account for individual variation among patients. They are not intended to supplant physician judgment with respect to particular patients or special clinical situations. IDSA considers adherence to these guidelines to be voluntary, with the ultimate determination regarding their application to be made by the physician in light of each patient's individual circumstances.

Correspondence: Douglas R. Osmon, Division of Infectious Diseases, Department of Internal Medicine, Mayo Clinic College of Medicine, 200 First St SW, Marian Hall 5, Rochester, MN 55905 (osmon.douglas@mayo.edu).

Clinical Infectious Diseases 2013;56(1):e1–25

© The Author 2012. Published by Oxford University Press on behalf of the Infectious Diseases Society of America. All rights reserved. For Permissions, please e-mail: journals.permissions@oup.com.

DOI: 10.1093/cid/cis803

Table 1. Strength of Recommendation and Quality of Evidence

Category/Grade	Definition
Strength of recommendation	
A	Good evidence to support a recommendation for or against use.
B	Moderate evidence to support a recommendation for or against use.
C	Poor evidence to support a recommendation.
Quality of evidence	
I	Evidence from >1 properly randomized, controlled trial.
II	Evidence from >1 well-designed clinical trial, without randomization; from cohort or case-controlled analytic studies (preferably from >1 center); from multiple time-series; or from dramatic results from uncontrolled experiments.
III	Evidence from opinions of respected authorities, based on clinical experience, descriptive studies, or reports of expert committees.

Source: [5]. Adapted and reproduced with the permission of the Minister of Public Works and Government Services Canada, 2009.

implement all the recommendations in these guidelines. Proper referral to specialty centers may need to occur.

Each section of the guideline begins with a specific clinical question and is followed by numbered recommendations and a summary of the most relevant evidence in support of the recommendations. The panel followed a process used in the development of other Infectious Diseases Society of America (IDSA) guidelines, which included a systematic weighting of the quality of the evidence and the grade of recommendation [5] (Table 1). A detailed description of the methods, background, and evidence summaries that support each of the recommendations can be found in the full text of the guideline. Areas of controversy in which data are limited or conflicting and where additional research is needed are indicated throughout the document and are highlighted in the “Research Gaps” section in the full text of the guideline.

I. What preoperative evaluation and intraoperative testing should be performed to diagnose PJI and what is the definition of PJI?

Recommendations

Preoperative Evaluation (Figure 1)

1. Suspect PJI in patients with any of the following (**B-III**): A sinus tract or persistent wound drainage over a joint prosthesis, acute onset of a painful prosthesis, or any chronic painful prosthesis at any time after prosthesis implantation, particularly in the absence of a pain-free interval, in the first few years following implantation or if there is a history of prior wound healing problems or superficial or deep infection.

2. Evaluation of the patient with a possible PJI should include a thorough history and physical examination (**C-III**). Items that should be obtained in the history include the type of prosthesis, date of implantation, past surgeries on the joint, history of wound healing problems following prosthesis implantation, remote infections, current clinical symptoms, drug allergies and intolerances, comorbid conditions, prior and current microbiology results from aspirations and surgeries, and antimicrobial therapy for the PJI including local antimicrobial therapy (**C-III**).

3. A test for sedimentation rate or C-reactive protein (CRP) should be performed in all patients with a suspected PJI when the diagnosis is not clinically evident. The combination of an abnormal sedimentation rate and CRP seems to provide the best combination of sensitivity and specificity (**A-III**).

4. A plain radiograph should be performed in all patients with suspected PJI (**A-III**).

5. A diagnostic arthrocentesis should be performed in all patients with suspected acute PJI unless the diagnosis is evident clinically and surgery is planned and antimicrobials can be safely withheld prior to surgery. Arthrocentesis is also advised in patients with a chronic painful prosthesis in whom there is an unexplained elevated sedimentation rate or CRP level (**A-III**) or in whom there is a clinical suspicion of PJI. It may not be necessary if in this situation surgery is planned and the result is not expected to alter management. Synovial fluid analysis should include a total cell count and differential leukocyte count, as well as culture for aerobic and anaerobic organisms (**A-III**). A crystal analysis can also be performed if clinically indicated.

6. In PJI where the patient is medically stable, withholding antimicrobial therapy for at least 2 weeks prior to collection of synovial fluid for culture increases the likelihood of recovering an organism (**B-III**).

7. Blood cultures for aerobic and anaerobic organisms should be obtained if fever is present, there is an acute onset of symptoms, or if the patient has a condition or suspected condition or concomitant infection or pathogen (eg *Staphylococcus aureus*) that would make the presence of a bloodstream infection more likely (**B-III**).

8. Imaging studies such as bone scans, leukocyte scans, magnetic resonance imaging, computed tomography, and positron emission tomography scans should not be routinely used to diagnose PJI (**B-III**).

Intraoperative Diagnosis of PJI

9. Intraoperative histopathological examination of periprosthetic tissue samples is a highly reliable diagnostic test provided that a pathologist skilled in interpretation of periprosthetic tissue is available. It should be performed at the time of revision prosthetic joint surgery, when available, if the presence of infection is in doubt based on the clinical suspicion of the

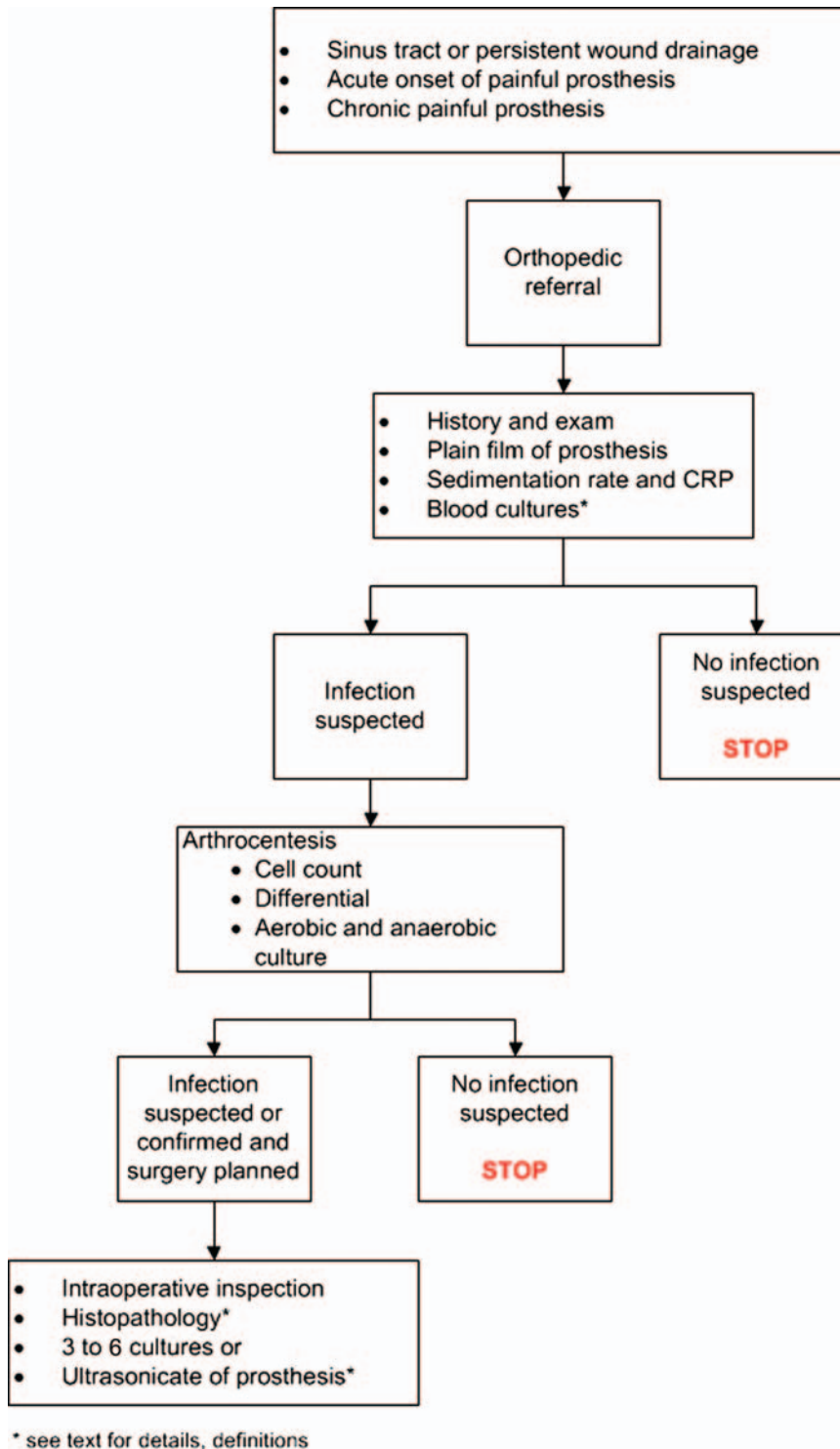


Figure 1. Preoperative and intraoperative diagnosis of prosthetic joint infection. Abbreviation: CRP, C-reactive protein.

surgeon and the results will affect management, for example, in deciding between revision arthroplasty and 2-stage exchange (B-III).

10. At least 3 and optimally 5 or 6 periprosthetic intraoperative tissue samples or the explanted prosthesis itself should be submitted for aerobic and anaerobic culture at

the time of surgical debridement or prosthesis removal to maximize the chance of obtaining a microbiologic diagnosis (B-II).

11. When possible (see above), withholding antimicrobial therapy for at least 2 weeks prior to collecting intraoperative culture specimens increases the yield of recovering an organism (A-II).

Definition of PJI

12. The presence of a sinus tract that communicates with the prosthesis is definitive evidence of PJI (B-III).

13. The presence of acute inflammation as seen on histopathologic examination of periprosthetic tissue at the time of surgical debridement or prosthesis removal as defined by the attending pathologist is highly suggestive evidence of PJI (B-II).

14. The presence of purulence without another known etiology surrounding the prosthesis is definitive evidence of PJI (B-III).

15. Two or more intraoperative cultures or combination of preoperative aspiration and intraoperative cultures that yield the same organism (indistinguishable based on common laboratory tests including genus and species identification or common antibiogram) may be considered definitive evidence of PJI. Growth of a virulent microorganism (eg, *S. aureus*) in a single specimen of a tissue biopsy or synovial fluid may also represent PJI. One of multiple tissue cultures or a single aspiration culture that yields an organism that is a common contaminant (eg, coagulase-negative staphylococci, *Propionibacterium acnes*) should not necessarily be considered evidence of definite PJI and should be evaluated in the context of other available evidence (B-III).

16. The presence of PJI is possible even if the above criteria are not met; the clinician should use his/her clinical judgment to determine if this is the case after reviewing all the available preoperative and intraoperative information (B-III).

II. What different surgical strategies should be considered for treatment of a patient with PJI?

Recommendations

17. The ultimate decision regarding surgical management should be made by the orthopedic surgeon with appropriate consultation (eg, infectious diseases, plastic surgery) as necessary (C-III).

18. Patients diagnosed with a PJI who have a well-fixed prosthesis without a sinus tract who are within approximately 30 days of prosthesis implantation or <3 weeks of onset of infectious symptoms should be considered for a debridement and retention of prosthesis strategy (Figure 2; A-II). Patients who do not meet these criteria but for whom alternative surgical strategies are unacceptable or high risk may also be

considered for a debridement and retention strategy, but relapse of infection is more likely (B-III).

19. A 2-stage exchange strategy is commonly used in the United States and is indicated in patients who are not candidates for a 1-stage exchange who are medically able to undergo multiple surgeries and in whom the surgeon believes reimplantation arthroplasty is possible, based on the existing soft tissue and bone defects (Figure 3; B-III). Obtaining a pre-revision sedimentation rate and CRP is recommended by the panel to assess the success of treatment prior to reimplantation (C-III). The panel believes that in selected circumstances more than one 2-stage exchange if the first attempt fails can be successful (C-III).

20. A 1-stage or direct exchange strategy for the treatment of PJI is not commonly performed in the United States but may be considered in patients with a total hip arthroplasty (THA) infection who have a good soft tissue envelope provided that the identity of the pathogens is known preoperatively and they are susceptible to oral antimicrobials with excellent oral bioavailability. There may be a greater risk of failure if bone grafting is required and effective antibiotic impregnated bone cement cannot be utilized (Figure 3; C-III).

21. Permanent resection arthroplasty may be considered in nonambulatory patients; patients with limited bone stock, poor soft tissue coverage, or infections due to highly resistant organisms for which there is limited medical therapy; patients with a medical condition precluding multiple major surgeries; or patients who have failed a previous 2-stage exchange in which the risk of recurrent infection after another staged exchange is deemed unacceptable (Figure 4; B-III).

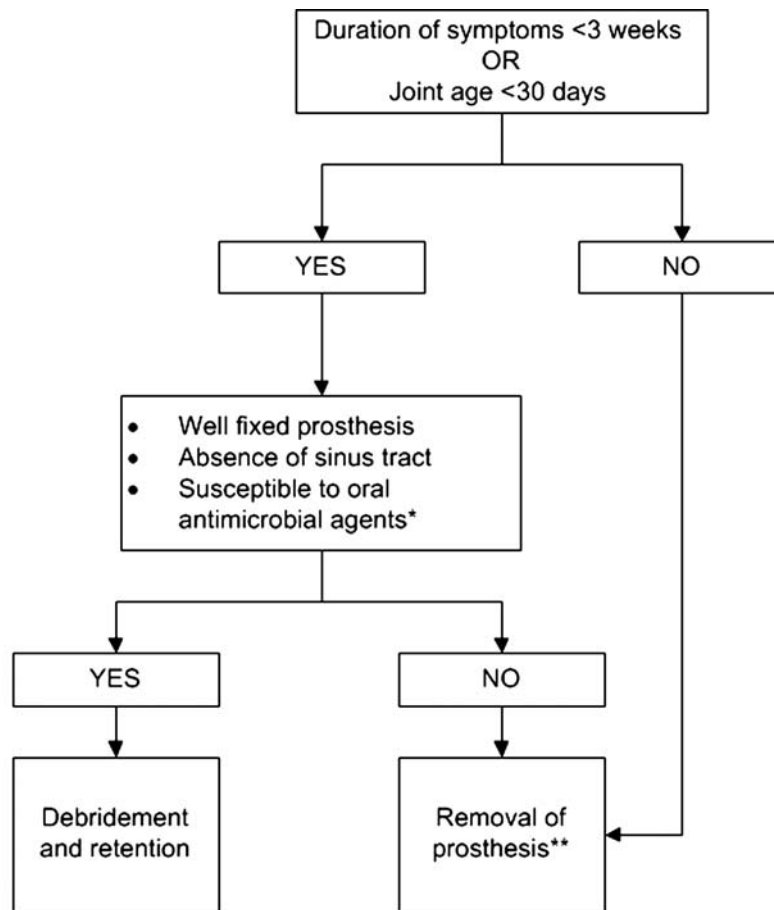
22. Amputation should be the last option considered but may be appropriate in selected cases. Except in emergent cases, referral to a center with specialist experience in the management of PJI is advised before amputation is carried out (Figure 4; B-III).

III. What is the medical treatment for a patient with PJI following debridement and retention of the prosthesis?

Recommendations

Staphylococcal PJI

23. Two to 6 weeks of a pathogen-specific intravenous antimicrobial therapy (Table 2) in combination with rifampin 300–450 mg orally twice daily followed by rifampin plus a companion oral drug for a total of 3 months for a THA infection and 6 months for a total knee arthroplasty (TKA) infection (A-I). Total elbow, total shoulder, and total ankle infections may be managed with the same protocols as THA infections (C-III). Recommended oral companion drugs for rifampin include ciprofloxacin (A-I) or levofloxacin (A-II).



*Antimicrobial agents that are recommended for prolonged use for chronic suppression or treatment of biofilm bacteria (see text for details)
 **See Figure 3 and recommendation 18 and accompanying Evidence Summary for possible exceptions

Figure 2. Management of prosthetic joint infection.

Secondary companion drugs to be used if in vitro susceptibility, allergies, intolerances, or potential intolerances support the use of an agent other than a quinolone include but are not limited to co-trimoxazole (A-II), minocycline or doxycycline (C-III), or oral first-generation cephalosporins (eg, cephalexin) or antistaphylococcal penicillins (eg, dicloxacillin; C-III). If rifampin cannot be used because of allergy, toxicity, or intolerance, the panel recommends 4–6 weeks of pathogen-specific intravenous antimicrobial therapy (B-III).

24. Monitoring of outpatient intravenous antimicrobial therapy should follow published guidelines (A-II) [6].

25. Indefinite chronic oral antimicrobial suppression may follow the above regimen with cephalexin, dicloxacillin, co-trimoxazole, or minocycline based on in vitro susceptibility, allergies, or intolerances (Table 3; B-III). Rifampin alone is

not recommended for chronic suppression, and rifampin combination therapy is not generally recommended. One member of the panel uses rifampin combination therapy for chronic suppression in selected situations (A. R. B.). The recommendation regarding using suppressive therapy after rifampin treatment was not unanimous (W. Z., D. L.). Clinical and laboratory monitoring for efficacy and toxicity is advisable. The decision to offer chronic suppressive therapy must take into account the individual circumstances of the patient including the ability to use rifampin in the initial phase of treatment, the potential for progressive implant loosening and loss of bone stock, and the hazards of prolonged antibiotic therapy; it is therefore generally reserved for patients who are unsuitable for, or refuse, further exchange revision, excision arthroplasty, or amputation.

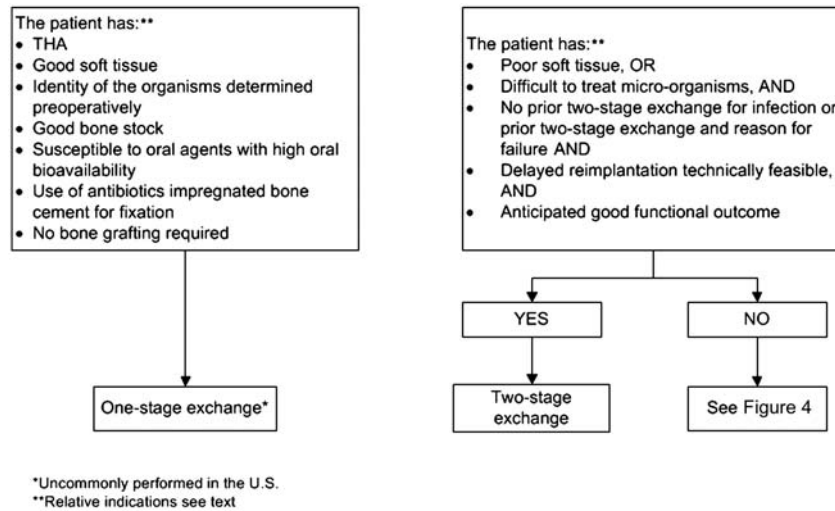


Figure 3. Management of prosthetic joint infection—removal of prosthesis. Abbreviation: THA, total hip arthroplasty.

PJI Due to Other Organisms

26. Four to 6 weeks of pathogen-specific intravenous or highly bioavailable oral antimicrobial therapy (Table 2; **B-II**).

27. Monitoring of outpatient intravenous antimicrobial therapy should follow published guidelines (**A-II**) [6].

28. Indefinite chronic oral antimicrobial suppression may follow the above regimens (Table 3) based on in vitro sensitivities, allergies, and intolerances (**B-III**). Chronic suppression after fluoroquinolone treatment of PJI due to gram-negative bacilli was not unanimously recommended (W. Z., D. L.). Clinical and laboratory monitoring for efficacy and toxicity is advisable. Similar considerations regarding hazards and effectiveness apply to those above.

IV. What is the medical treatment for a patient with PJI following resection arthroplasty with or without planned staged reimplantation?

Recommendations

29. Four to 6 weeks of pathogen-specific intravenous or highly bioavailable oral antimicrobial therapy is recommended (Table 2; **A-II**).

30. Monitoring of outpatient intravenous antimicrobial therapy should follow published guidelines (**A-II**) [6].

V. What is the medical treatment for a patient with PJI following 1-stage exchange?

Recommendations

Staphylococcal PJI

31. Two to 6 weeks of pathogen-specific intravenous antimicrobial therapy in combination with rifampin 300–450 mg

orally twice daily followed by rifampin plus a companion oral drug for a total of 3 months is recommended (Table 2; **C-III**). Recommended oral companion drugs for rifampin include ciprofloxacin (**A-I**) or levofloxacin (**A-II**). Secondary companion drugs to be used if in vitro susceptibility, allergies, intolerances, or potential intolerances support the use of an agent other than a quinolone include but are not limited to co-trimoxazole (**A-II**), minocycline or doxycycline (**B-III**), or oral first-generation cephalosporins (eg, cephalexin) or antistaphylococcal penicillins (eg, dicloxacillin; **C-III**). If rifampin cannot be used because of allergy, toxicity, or intolerance, then the panel recommends 4–6 weeks of pathogen-specific intravenous antimicrobial therapy.

32. Monitoring of outpatient intravenous antimicrobial therapy should follow published guidelines (**A-II**) [6].

33. Indefinite chronic oral antimicrobial suppression may follow the above regimen with either cephalexin, dicloxacillin, co-trimoxazole, or minocycline or doxycycline based on in vitro susceptibility, allergies, or intolerances (Table 3; **B-III**). Rifampin alone is not recommended for chronic suppression, and rifampin combination therapy is also not generally recommended. One member of the panel uses rifampin combination therapy for chronic suppression in selected situations (A. R. B.). The recommendation regarding using suppressive therapy after rifampin treatment was not unanimous (D. L., W. Z.). Clinical and laboratory monitoring for efficacy and toxicity is advisable. The decision to offer chronic suppressive therapy must take into account the individual circumstances of the patient including the ability to use rifampin in the initial phase of treatment, the potential for progressive

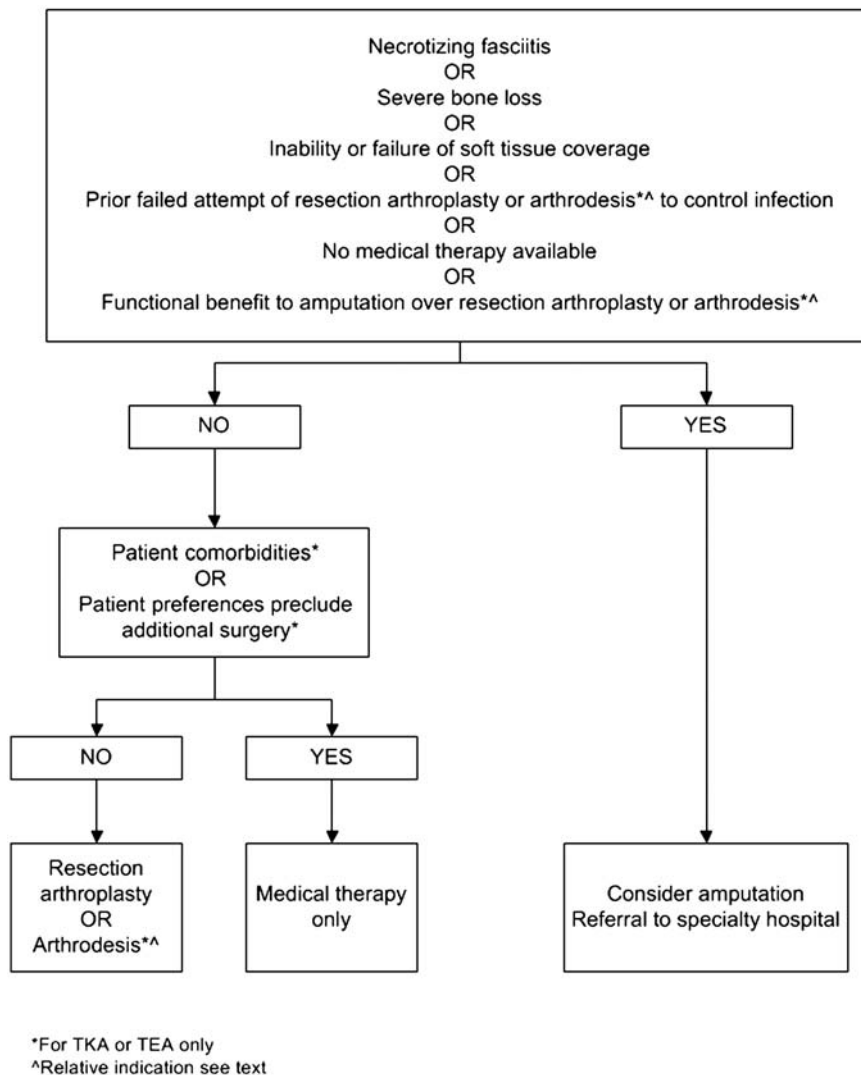


Figure 4. Management of prosthetic joint infection when patients are not a candidate for new prosthesis. Abbreviations: TEA, total elbow arthroplasty; TKA, total knee arthroplasty.

implant loosening and loss of bone stock, and the hazards of prolonged antibiotic therapy; it is therefore generally reserved for patients who are unsuitable for, or refuse, further exchange revision, excision arthroplasty, or amputation.

PJI Due to Other Organisms

34. Four to 6 weeks of pathogen-specific intravenous or highly bioavailable oral antimicrobial therapy is recommended (Table 2; A-II).

35. Monitoring of outpatient intravenous antimicrobial therapy should follow published guidelines (A-II) [6].

36. Indefinite chronic oral antimicrobial suppression should follow regimens in Table 3 and be based on in vitro sensitivities, allergies, and intolerances (B-III). Chronic suppression after fluoroquinolone treatment of gram-negative

bacilli was not unanimously recommended (D. L., W. Z.). Clinical and laboratory monitoring for efficacy and toxicity is advisable. Similar considerations regarding hazards and effectiveness apply to those above.

VI. What is the medical treatment for a patient with PJI following amputation?

37. Pathogen-specific antimicrobial therapy should be given until 24–48 hours after amputation assuming all infected bone and soft tissue has been surgically removed and there is no concomitant sepsis syndrome or bacteremia. If sepsis syndrome or bacteremia are present, treatment duration is to be according to recommendations for these syndromes (C-III).

Table 2. Intravenous or Highly Bioavailable Oral Antimicrobial Treatment of Common Microorganisms Causing Prosthetic Joint Infection (B-III Unless Otherwise Stated in Text)

Microorganism	Preferred Treatment ^a	Alternative Treatment ^a	Comments
Staphylococci, oxacillin-susceptible	Nafcillin ^b sodium 1.5–2 g IV q4-6 h or Cefazolin 1–2 g IV q8 h or Ceftriaxone ^c 1–2 g IV q24 h	Vancomycin IV 15 mg/kg q12 h or Daptomycin 6 mg/kg IV q 24 h or Linezolid 600 mg PO/IV every 12 h	See recommended use of rifampin as a companion drug for rifampin-susceptible PJI treated with debridement and retention or 1-stage exchange in text
Staphylococci, oxacillin-resistant	Vancomycin ^d IV 15 mg/kg q12 h	Daptomycin 6 mg/kg IV q24 h or Linezolid 600 mg PO/IV q12 h	See recommended use of rifampin as a companion drug for rifampin-susceptible PJI treated with debridement and retention or 1-stage exchange in text
<i>Enterococcus</i> spp, penicillin-susceptible	Penicillin G 20–24 million units IV q24 h continuously or in 6 divided doses or Ampicillin sodium 12 g IV q24 h continuously or in 6 divided doses	Vancomycin 15 mg/kg IV q12 h or Daptomycin 6 mg/kg IV q24 h or Linezolid 600 mg PO or IV q12 h	4–6 wk. Aminoglycoside optional Vancomycin should be used only in case of penicillin allergy
<i>Enterococcus</i> spp, penicillin-resistant	Vancomycin 15 mg/kg IV q12 h	Linezolid 600 mg PO or IV q12 h or Daptomycin 6 mg IV q24 h	4–6 wk. Addition of aminoglycoside optional
<i>Pseudomonas aeruginosa</i>	Cefepime 2 g IV q12 h or Meropenem ^e 1 g IV q8 h	Ciprofloxacin 750 mg PO bid or 400 mg IV q12 h or Ceftazidime 2 g IV q8 h	4–6 wk Addition of aminoglycoside optional Use of 2 active drugs could be considered based on clinical circumstance of patient. If aminoglycoside in spacer, and organism aminoglycoside susceptible than double coverage being provided with recommended IV or oral monotherapy
<i>Enterobacter</i> spp	Cefepime 2 g IV q12 h or Ertapenem 1 g IV q24 h	Ciprofloxacin 750 mg PO or 400 mg IV q12 h	4–6 wk.
Enterobacteriaceae	IV β -lactam based on in vitro susceptibilities or Ciprofloxacin 750 mg PO bid		4–6 wk
β -hemolytic streptococci	Penicillin G 20–24 million units IV q24 h continuously or in 6 divided doses or Ceftriaxone 2 g IV q24 h	Vancomycin 15 mg/kg IV q12 h	4–6 wk Vancomycin only in case of allergy

Table 2 continued.

Microorganism	Preferred Treatment ^a	Alternative Treatment ^a	Comments
<i>Propionibacterium acnes</i>	Penicillin G 20 million units IV q24 h continuously or in 6 divided doses or Ceftriaxone 2 g IV q24 h	Clindamycin 600–900 mg IV q8 h or clindamycin 300–450 mg PO qid or Vancomycin 15 mg/kg IV q12 h	4–6 wk Vancomycin only in case of allergy

Abbreviations: bid, twice daily; IV, intravenous; PJI, prosthetic joint infection; q, every; PO, per oral; qid, 4 times daily.

^a Antimicrobial dosage needs to be adjusted based on patients' renal and hepatic function. Antimicrobials should be chosen based on in vitro susceptibility as well as patient drug allergies, intolerances, and potential drug interactions or contraindications to a specific antimicrobial. Clinical and laboratory monitoring for efficacy and safety should occur based on prior IDSA guidelines [6]. The possibility of prolonged QTc interval and tendinopathy should be discussed and monitored when using fluoroquinolones. The possibility of *Clostridium difficile* colitis should also be discussed when using any antimicrobial.

^b Flucloxacillin may be used in Europe. Oxacillin can also be substituted.

^c There was not a consensus on the use of ceftriaxone for methicillin-susceptible staphylococci (see text).

^d Target troughs for vancomycin should be chosen with the guidance of a local infectious disease physician based on the pathogen, its in vitro susceptibility, and the use of rifampin or local vancomycin therapy. Recent guidelines [155, 164] for the treatment of methicillin-resistant *Staphylococcus aureus* (MRSA) infections have been published. (These guidelines suggest that dosing of vancomycin be considered to achieve a vancomycin trough at steady state of 15 to 20. Although this may be appropriate for MRSA PJI treated without rifampin or without the use of local vancomycin spacer, it is unknown if these higher trough concentrations are necessary when rifampin or vancomycin impregnated spacers are utilized. Trough concentrations of at least 10 may be appropriate in this situation. It is also unknown if treatment of oxacillin-resistant, coagulase-negative staphylococci require vancomycin dosing to achieve these higher vancomycin levels.)

^e Other antipseudomonal carbapenems can be utilized as well.

38. Four to 6 weeks of pathogen-specific intravenous or highly bioavailable oral antimicrobial therapy is recommended if, despite surgery, there is residual infected bone and soft tissue (ie, hip disarticulation for THA infection, long-stem TKA prosthesis where the prosthesis extended above the level of amputation; Table 2; C-III).

39. Monitoring of outpatient intravenous antimicrobial therapy should follow published guidelines (A-II) [6].

INTRODUCTION

Joint replacement is a highly effective intervention that significantly improves patients' quality of life, providing symptom relief, restoration of limb or joint function, improved mobility, and independence. Prosthetic joint infection (PJI) remains one of the most serious complications of prosthetic joint implantation. The cumulative incidence of PJI among the approximately 1 000 000 primary total hip arthroplasties (THAs) and total knee arthroplasties (TKAs) performed in the United States in 2009 is approximately 1%–2% over the lifetime of the prosthetic joint, depending on the type of prosthesis and whether the surgery is a primary or revision procedure [2, 7–10]. The number of PJI is likely to increase: It is projected that by the year 2030, approximately 4 million THAs and TKAs will be performed per year in the United States [11].

The diagnosis of PJI can be difficult and utilizes many different diagnostic modalities including serologic, radiographic, and microbiologic diagnostic tests. The management of PJI often necessitates the need for surgical interventions and prolonged courses of intravenous and oral antimicrobial therapy [1–4]. Despite a significant amount of basic and clinical research in this field, many questions pertaining to the optimal diagnostic strategies and management of these infections remain unanswered. The primary focus of these guidelines will be to provide a consensus statement that addresses selected current controversies in the diagnosis and treatment of infections involving prosthetic joints. In many situations, the panel has made recommendations based on expert opinion, realizing that the amount of data to support a specific recommendation is limited, and that there are diverse practice patterns which seem to be equally effective for a given clinical problem.

An essential component of this therapeutic approach is the strong collaboration between all involved medical and surgical specialists (eg, orthopedic surgeons, plastic surgeons, infectious disease specialists, general internists). It is anticipated that consideration of these guidelines may help reduce morbidity, mortality, and the costs associated with PJI. The panel realizes that not all medical institutions will have the necessary resources to implement all the recommendations in these guidelines. Proper referral may need to occur.

Table 3. Common Antimicrobials Used for Chronic Oral Antimicrobial Suppression (B-III Unless Otherwise Stated in Text)^{a,b}

Microorganism	Preferred Treatment	Alternative Treatment
Staphylococci, oxacillin-susceptible	Cephalexin 500 mg PO tid or qid or Cefadroxil 500 mg PO bid	Dicloxacillin 500 mg PO tid or qid Clindamycin 300 mg PO qid Amoxicillin-clavulanate 500 mg PO tid
Staphylococci, oxacillin-resistant	Cotrimoxazole 1 DS tab PO bid Minocycline or doxycycline 100 mg PO bid	
β -hemolytic streptococci	Penicillin V 500 mg PO bid to qid or Amoxicillin 500 mg PO tid	Cephalexin 500 mg PO tid or qid
<i>Enterococcus</i> spp, penicillin susceptible	Penicillin V 500 mg PO bid to qid or Amoxicillin 500 mg PO tid	
<i>Pseudomonas aeruginosa</i>	Ciprofloxacin 250–500 mg PO bid	
Enterobacteriaceae	Cotrimoxazole 1 DS tab PO bid	β -lactam oral therapy based on in vitro susceptibilities
<i>Propionibacterium</i> spp	Penicillin V 500 mg PO bid to qid or Amoxicillin 500 mg PO tid	Cephalexin 500 mg PO tid or qid Minocycline or doxycycline 100 mg PO bid

Abbreviations: bid, twice daily; DS, double strength; PO, per oral; qid, 4 times daily; tid, 3 times daily.

^a Antimicrobial dosage needs to be adjusted based on patients' renal and hepatic function. Antimicrobials should be chosen based on in vitro susceptibility as well as patient drug allergies, intolerances, and potential drug interactions or contraindications to a specific antimicrobial.

^b Clinical and laboratory monitoring for efficacy and safety should occur based on the clinical judgment of the clinician caring for the patient. The possibility of prolonged QTc interval and tendinopathy should be discussed and monitored when using fluoroquinolones. The possibility of *Clostridium difficile* colitis should also be discussed when using any antimicrobial.

The panel addressed the following clinical questions:

- (I) What preoperative evaluation and intraoperative testing should be performed to diagnose PJI and what is the definition of PJI?
- (II) What different surgical strategies should be considered for treatment of a patient with PJI?
- (III) What is the medical treatment for a patient with PJI following debridement and retention of the prosthesis?
- (IV) What is the medical treatment for a patient with PJI following resection arthroplasty with or without planned staged reimplantation?
- (V) What is the medical treatment for a patient with PJI following 1-stage exchange?
- (VI) What is the medical treatment for a patient with PJI following amputation?

PRACTICE GUIDELINES

“Practice guidelines are systematically developed statements to assist practitioners and patients in making decisions about appropriate health care for specific clinical circumstances” [12]. Attributes of good guidelines include validity, reliability, reproducibility, clinical applicability, clinical flexibility, clarity, multidisciplinary process, review of evidence, and documentation [12].

METHODOLOGY

Panel Composition

A panel of infectious disease specialists and an orthopedist, drawn from North America and Europe, who are experts in PJI was convened. The panelists had both clinical and laboratory experience with PJI.

Literature Review and Analysis

Two members of the panel (D. R. O., E. F. B.) initially reviewed the existing literature. The literature search, which included the MEDLINE database between 1966 and 2011, Cochrane library database, MD Consult, Up to Date, and the National Guidelines Clearinghouse, was performed on multiple occasions, the last being in April 2011 using multiple search terms such as “joint prosthesis” and “PJI.” Hand searching of bibliographies of identified articles was also undertaken.

Process Overview

In evaluating the evidence regarding the management of PJI, the panel followed a process used in the development of other Infectious Diseases Society of America (IDSA) guidelines. The process included a systematic weighting of the quality of the evidence and the grade of recommendation (Table 1) [5]. Recommendations for the medical management of PJI were

derived primarily from case reports, nonrandomized retrospective case series, and 1 single-center randomized clinical trial.

Consensus Development Based on Evidence

Two members of the panel (D. R. O., E. F. B.) initially reviewed existing literature and formulated a first draft of the guidelines. This first draft was circulated electronically to all members of the panel for comments and review. D. R. O. and E. F. B. then incorporated these comments into a second and third draft that was reviewed electronically. Topics on which consensus could not be reached were discussed by the panel members electronically, by teleconferences, and in person. All members of the panel approved the final draft. Feedback from external peer reviews was obtained and changes made after review with the entire panel. The guideline was reviewed and approved by the IDSA Standards and Practice Guidelines Committee (SPGC) and the Board of Directors prior to dissemination.

Guidelines and Conflicts of Interest

All members of the expert panel complied with the IDSA policy on conflicts of interest, which requires disclosure of any financial or other interest that might be construed as constituting an actual, potential, or apparent conflict. Members of the expert panel were provided IDSA's conflicts of interest disclosure statement and were asked to identify ties to companies developing products that might be affected by promulgation of the guideline. Information was requested regarding employment, consultancies, stock ownership, honoraria, research funding, expert testimony, and membership on company advisory committees. The panel made decisions on a case-by-case basis as to whether an individual's role should be limited as a result of a conflict. Potential conflicts are listed in the "Notes" section at the end of the guideline.

Revision Dates

At annual intervals, the panel chair, the SPGC liaison advisor, and the chair of the SPGC will determine the need for revisions to the guideline on the basis of an examination of the current literature. If necessary, the entire panel will be reconvened to discuss potential changes. When appropriate, the panel will recommend revision of the guideline to the SPGC and the IDSA Board for review and approval.

RECOMMENDATIONS FOR THE DIAGNOSIS AND TREATMENT OF PJIs

I. What preoperative evaluation and intraoperative testing should be performed to diagnose PJI and what is the definition of PJI?

Recommendations

Preoperative Evaluation (Figure 1)

1. Suspect PJI in patients with any of the following (B-III): A sinus tract or persistent wound drainage over a joint

prosthesis, acute onset of a painful prosthesis, or any chronic painful prosthesis at any time after prosthesis implantation, particularly in the absence of a pain-free interval in the first few years following implantation or if there is a history of prior wound healing problems or superficial or deep infection.

2. Evaluation of the patient with a possible PJI should include a thorough history and physical examination (C-III). Items that should be obtained in the history include the type of prosthesis, date of implantation, past surgeries on the joint, history of wound healing problems following prosthesis implantation, remote infections, current clinical symptoms, drug allergies and intolerances, comorbid conditions, prior and current microbiology results from aspirations and surgeries, and antimicrobial therapy for the PJI including local antimicrobial therapy (C-III).

3. A test for sedimentation rate or C-reactive protein (CRP) should be performed in all patients with a suspected PJI when the diagnosis is not clinically evident. The combination of an abnormal sedimentation rate and CRP seems to provide the best combination of sensitivity and specificity (A-III).

4. A plain radiograph should be performed in all patients with suspected PJI (A-III).

5. A diagnostic arthrocentesis should be performed in all patients with suspected acute PJI unless the diagnosis is evident clinically and surgery is planned and antimicrobials can be safely withheld prior to surgery. Arthrocentesis is also advised in patients with a chronic painful prosthesis in whom there is an unexplained elevated sedimentation rate or CRP (A-III) or in whom there is a clinical suspicion of PJI. It may not be necessary if in this situation surgery is planned and the result is not expected to alter management. Synovial fluid analysis should include a total cell count and differential leukocyte count, as well as culture for aerobic and anaerobic organisms (A-III). A crystal analysis can also be performed if clinically indicated.

6. In PJI where the patient is medically stable, withholding antimicrobial therapy for at least 2 weeks prior to collecting synovial fluid for culture increases the likelihood of recovering an organism (B-III).

7. Blood cultures for aerobic and anaerobic organisms should be obtained if fever is present, there is an acute onset of symptoms, or if the patient has a condition or suspected condition or concomitant infection or pathogen (eg, *Staphylococcus aureus*) that would make the presence of a bloodstream infection more likely (B-III).

8. Imaging studies such as bone scans, leukocyte scans, magnetic resonance imaging (MRI), computed tomography (CT), and positron emission tomography (PET) scans should not be routinely used to diagnose PJI (B-III).

Intraoperative Diagnosis of PJI

9. Intraoperative histopathological examination of periprosthetic tissue samples is a highly reliable diagnostic test provided

that a pathologist skilled in interpretation of periprosthetic tissue is available. It should be performed at the time of revision prosthetic joint surgery, when available, if the presence of infection is in doubt based on the clinical suspicion of the surgeon and the results will affect management, for example, in deciding between revision arthroplasty and 2-stage exchange (B-III).

10. At least 3 and optimally 5 or 6 periprosthetic intraoperative tissue samples or the explanted prosthesis itself should be submitted for aerobic and anaerobic culture at the time of surgical debridement or prosthesis removal to maximize the chance of obtaining a microbiologic diagnosis (B-II).

11. When possible (see above), withholding antimicrobial therapy for at least 2 weeks prior to collecting intraoperative culture specimens increases the yield of recovering an organism (A-II).

Definition of PJI

12. The presence of a sinus tract that communicates with the prosthesis is definitive evidence of PJI (B-III).

13. The presence of acute inflammation as seen on histopathologic examination of the periprosthetic tissue at the time of surgical debridement or prosthesis removal as defined by the attending pathologist is highly suggestive evidence of PJI (B-II).

14. The presence of purulence without another known etiology surrounding the prosthesis is definitive evidence of PJI (B-III).

15. Two or more intraoperative cultures or combination of preoperative aspiration and intraoperative cultures that yield the same organism (indistinguishable based on common laboratory tests including genus and species identification or common antibiogram) may be considered definitive evidence of PJI. Growth of a virulent microorganism (eg, *S. aureus*) in a single specimen of a tissue biopsy or synovial fluid may also represent PJI. One of multiple tissue cultures or a single aspiration culture that yields an organism that is a common contaminant (eg, coagulase-negative staphylococci, *Propionibacterium acnes*) should not necessarily be considered evidence of definite PJI and should be evaluated in the context of other available evidence (B-III).

16. The presence of PJI is possible even if the above criteria are not met; the clinician should use his/her clinical judgment to determine if this is the case after reviewing all the available preoperative and intraoperative information (B-III).

Evidence Summary

Diagnosis: Preoperative Evaluation

Classification schemes for PJI are based on the timing of infection after prosthesis implantation and a presumptive mechanism of infection [13, 14]. These schemes may help the clinician decide on treatment options. Infections that occur within 1–3 months after implantation are classified as “early”

whereas infections that occur several months to 1–2 years following prosthesis implantation are classified as delayed. Both types of infection are believed to be acquired most often during prosthesis implantation. Early infections often will present with local signs of cellulitis, erythema, swelling, pain, drainage, and delayed wound healing and may or may not have systemic symptoms such as fever and chills [4, 15]. Delayed infection, as well as chronic infection occurring many years after prosthesis insertion, typically presents with vague symptoms such as chronic pain without systemic symptoms as well as a loose prosthesis. These scenarios can be difficult to distinguish from aseptic loosening by history and physical exam. Although any painful prosthesis can represent a PJI, the absence of an obvious mechanical reason for a painful prosthesis in the first few years following implantation, a history of prior wound healing problems, or superficial or deep infection should also raise the suspicion of PJI.

Late infections that occur more than 1–2 years after prosthesis implantation are either due to hematogenous seeding of the prosthesis or a late manifestation of an infection acquired during prosthesis insertion. Hematogenous infections may also occur early after prosthesis insertion [16]. Late infections are often characterized by an acute septic arthritis syndrome with sudden onset of pain in the setting of concomitant or recent infection occurring elsewhere in the body (eg, skin and soft tissue, respiratory tract, or urinary tract infections) [13, 14, 16–18].

At the time of diagnosis of PJI, information related to the type of prosthesis, date of implantation, past surgeries on the joint, clinical symptoms, drug allergies and intolerances, comorbid conditions, and prior and current antimicrobial therapy for the PJI including local antimicrobial therapy should be obtained by the clinician [19, 20].

A variety of laboratory and radiographic tests are available to aid the clinician in the diagnosis of PJI in situations where the diagnosis is unclear [21–23]. Plain radiographs are obtained in most if not all situations but lack sensitivity and specificity [24]. They rarely show clear evidence of infection such as transcortical sinus tract but can show other reasons for chronic pain and serve as a baseline for following any diagnostic or therapeutic procedures. Serial exams may be the most helpful. Radionuclide scans, CT, MRI, and FDG PET scanning are rarely utilized due to either their expense, lack of availability, or image distortion due to the prosthesis compared with other tests [1, 4, 22]. If any of these tests are utilized, a leukocyte scan in combination with a technetium-labeled bone scan is the most often used because of availability and reasonable sensitivity and specificity. The utility of the white blood cell count, CRP, and erythrocyte sedimentation rate have been discussed at length by multiple authors [1, 4, 21, 25, 26]. These tests are obviously not necessary to make a

diagnosis when infection is evident, for example, when a sinus tract is present or there is an acute septic arthritis. They are nonspecific tests and are associated with a significant false-positive rate particularly immediately after prosthesis implantation or in patients with inflammatory arthritis [21]. Cutoffs that predict PJI in this setting have recently been proposed but require validation [27]. Baseline values if available may be helpful. CRP seems to be more accurate than the sedimentation rate when evaluating a patient with a painful prosthesis and suspected chronic PJI [21, 26, 28, 29]. Combining both the sedimentation rate and the CRP so that either both are positive or both are negative may provide the best combination of positive and negative predictive values [21, 28–30]. There are much less data on the use of interleukin 6 (IL-6) and procalcitonin, although IL-6 looks very promising [26, 31, 32]. Blood cultures to exclude concomitant bacteremia should be obtained if the patient is febrile, has a clinical condition or concomitant infection, or has a pathogen known to cause metastatic infection (eg, *S. aureus*) that would make bacteremia more likely. Suspicion of infective endocarditis or the presence of a cardiac pacemaker, for example, should also warrant the consideration of obtaining blood cultures and, depending on the level of suspicion of the presence of infective endocarditis, a transesophageal echocardiogram.

Synovial fluid obtained by preoperative aspiration can be submitted for cell count and differential, Gram stain, and aerobic and anaerobic culture. A diagnostic arthrocentesis should be performed in all patients with a suspected acute PJI unless the diagnosis is evident clinically and surgery is planned and antimicrobials can be withheld prior to surgery. Arthrocentesis is also advised in patients with a chronic painful prosthesis in whom there is an elevated sedimentation rate or CRP level or in whom there is a high clinical suspicion of PJI. It may not be necessary in this situation if surgery is planned and the result is not expected to alter management [19, 21, 22, 30, 33]. A synovial fluid leukocyte differential of >65% neutrophils or a leukocyte count of >1700 cells/ μ L had 97% and 94% sensitivity, respectively, to detect infection in a total knee replacement in patients without underlying inflammatory joint disease and who were more than 6 months from TKA implantation [34]. This cutoff is much lower than that used to suggest infection in native joint septic arthritis. In all patients with a THA-associated infection in a recent study, a leukocyte count of 4200 cells/ μ L had a sensitivity of 84% and a specificity of 93% to detect PJI [35]. Its utility in other types of prostheses is the subject of ongoing research. A synovial fluid leukocyte count >27 800 cells/ μ L and differential of 89% polymorphonuclear neutrophils has recently been shown to be predictive of TKA infection in the early postoperative period [27]. Thus the cell count and its ability to predict infection must be interpreted in light of the type of prosthesis and the time from prosthesis implantation.

Diagnosis: Intraoperative Evaluation

Intraoperative histopathological examination of the periprosthetic tissue has a relatively high sensitivity (>80%) and specificity (>90%) and is used to decide if revision arthroplasty vs resection arthroplasty should be performed when a skilled pathologist is available and the preoperative evaluation has failed to confirm PJI [21, 30, 36–38]. Unfortunately, the results can be dependent on appropriate sampling of the tissue harboring the infection and the expertise of the pathologist since not all centers will have pathologists who are experienced in this type of histopathologic analysis. There are recent data suggesting that acute inflammation is less common in infection due to low-virulence organisms [39].

At least 3 and optimally 5 or 6 periprosthetic intraoperative samples from the most suspicious areas of tissue as deemed by the orthopedic surgeon should be obtained for aerobic and anaerobic culture for the optimal diagnosis of PJI [40, 41]. Submitting fewer than 5–6 specimens leads to a decrease in sensitivity of culture as a diagnostic test. There is no standard time that microbiology laboratories incubate periprosthetic tissue specimens. The optimal duration of incubation of periprosthetic tissue specimens is unknown, but prolonged incubation of up to 14 days may help with pathogen isolation, particularly *Propionibacterium* species, a common pathogen in total shoulder arthroplasty infection [42]. Novel processing techniques may also help with pathogen identification [43]. When possible, withholding antimicrobial therapy for at least 2 weeks prior to collecting the specimens increases the yield of recovering an organism [41]. The decision to withhold antimicrobial prophylaxis at the time of revision total joint surgery to optimize tissue culture ascertainment should be based on the preoperative risk of PJI. If the risk is low based on the results of the history, exam, sedimentation rate, CRP level, and preoperative aspiration, then antimicrobial prophylaxis should be given normally according to standard guidelines. If the risk of PJI is high, then withholding antimicrobial prophylaxis prior to revision total joint surgery seems appropriate to maximize the yield of tissue cultures. The explanted prosthesis itself can also be submitted for Sonication and subsequent aerobic and anaerobic culture. Sonication has been used to dislodge bacteria from the surface of the prosthesis, and culture of the prosthesis ultrasonicate can improve the sensitivity of aerobic and anaerobic culture compared to traditional tissue culture [41, 44]. The sensitivity of a periprosthetic sonicate-fluid culture for the diagnosis of prosthetic hip and knee infection was higher than that of culturing a single sample of periprosthetic tissue, namely, 78.5% compared with 60.8% ($P < .001$) in the original study utilizing this technique [41]. This technique is not validated for the isolation of fungal and mycobacterial organisms. The Gram stain is not routinely useful as a diagnostic test owing to low sensitivity on tissue

specimens but has increased sensitivity on ultrasonicate fluid [40, 41, 45, 46]. As with other uses, false-positive Gram stains due to laboratory contamination have been reported [47]. In the situation of a positive Gram stain and negative tissue cultures, the clinician will need to decide after review of the clinical circumstances of the specific case, including the use of prior antimicrobial therapy, and discussion with the microbiology laboratory if the Gram stain result is helpful in tailoring antimicrobial therapy. Rapid diagnostic tests such as polymerase chain reaction are still not yet available for routine clinical application [48–50].

Definition of PJI

There is no standard definition of what constitutes PJI; therefore, interpretation of the literature related to the treatment of these infections is difficult [51]. The diagnosis of PJI is obvious if multiple cultures from specimens surrounding the prosthesis yield identical microorganisms, if the prosthesis ultrasonicate fluid is positive, if purulence is observed surrounding the prosthesis without another known etiology such as a failed metal-on-metal arthroplasty [52], or if a sinus tract that communicates with the prosthetic device is present. The diagnosis of PJI can be more difficult if typical signs or symptoms of infection are lacking. For instance, the presence of periprosthetic loosening of a joint arthroplasty or joint pain can be the result of occult infection or other non-infectious etiologies. The presence of acute inflammation consistent with infection on histopathological examination (as determined by a pathologist) is highly suggestive evidence of the presence of PJI (though it should be noted that there are multiple definitions of what constitutes acute inflammation of periprosthetic tissues at the time of revision arthroplasty and significant variability among pathologists in the interpretation of these specimens) [21, 36–38, 53]. The panel is of the opinion that 2 or more positive cultures from intraoperative specimens represent definitive evidence of infection. Although a study by Atkins et al found an optimal posttest probability of infection with 3 or more positive cultures, they also demonstrated that at the time of revision hip or knee surgery, compared with histopathologic evidence of infection, 2 positive intraoperative cultures provided acceptable sensitivity and specificity without requiring an impractical amount of tissue specimens to be processed by the laboratory [40]. A single positive periprosthetic tissue culture that yields an organism that is a common contaminant (eg, coagulase-negative staphylococci, *Propionibacterium acnes*) should not necessarily be considered evidence of definite PJI and should be evaluated in the context of other available evidence [40, 51]. The clinician should use clinical judgment when the presence of PJI is not obvious and decide if infection is present after reviewing the history, exam, and preoperative and intraoperative tests.

II. What different surgical strategies should be considered for treatment of a patient with PJI?

Recommendations

17. The ultimate decision regarding surgical management should be made by the orthopedic surgeon with appropriate consultation (eg, infectious diseases, plastic surgery) as necessary (C-III).

18. Patients diagnosed with a PJI who have a well-fixed prosthesis without a sinus tract who are within approximately 30 days of prosthesis implantation or fewer than 3 weeks of onset of infectious symptoms should be considered for a debridement and retention of prosthesis strategy (Figure 2; A-II). Patients who do not meet these criteria but for whom alternative surgical strategies are unacceptable or high risk may also be considered for a debridement and retention strategy, but relapse of infection is more likely (B-III).

19. A 2-stage exchange strategy is commonly used in the United States and is indicated in patients who are not candidates for a 1-stage exchange who are medically able to undergo multiple surgeries and in whom the surgeon believes reimplantation arthroplasty is possible, based on the existing soft tissue and bone defects (Figure 3; B-III). Obtaining a pre-revision sedimentation rate and CRP is recommended by the panel to assess the success of treatment prior to reimplantation (C-III). The panel believes that in selected circumstances, more than one 2-stage exchanges can be successful if the first one fails (C-III).

20. A 1-stage or direct exchange strategy for the treatment of PJI is not commonly performed in the United States but may be considered in patients with a THA infection who have a good soft tissue envelope provided that the identity of the pathogens is known preoperatively and susceptible to oral antimicrobials with excellent oral bioavailability. There may be a greater risk of failure if bone grafting is required and effective antibiotic impregnated bone cement cannot be utilized (Figure 3; C-III).

21. Permanent resection arthroplasty may be considered in nonambulatory patients; patients with limited bone stock, poor soft tissue coverage, or infections due to highly resistant organisms for which there is limited medical therapy; patients with a medical condition precluding multiple major surgeries; or patients who have failed a previous 2-stage exchange in which the risk of recurrent infection after another staged exchange is deemed unacceptable (Figure 4; B-III).

22. Amputation should be the last option considered but may be appropriate in selected cases. Except in emergent cases, referral to a center with specialist experience in the management of PJI is advised before amputation is carried out (Figure 4; B-III).

Evidence Summary

The most commonly used surgical treatments for PJI include debridement and retention of the prosthesis, 1- or 2-stage

(staged) exchange, resection arthroplasty, arthrodesis, and amputation [54]. There are no published randomized clinical trials to address optimal selection of these surgical procedures. The available data consist of single-center noncomparative cohort studies and a decision analysis based on these cohort studies [55]. Infectious disease clinicians should work closely with the orthopedist to determine the ultimate surgical strategy selected for an individual patient.

Many factors influence the ultimate surgical management chosen for a given patient. Examples of these factors could include duration of symptoms, joint age (early, delayed, or late), infecting pathogen and its susceptibility pattern, prosthesis stability, and the patient's preexisting medical comorbidities. Other factors, such as the quality of the periprosthetic soft tissue, the options available for successful reconstructive surgery after resection arthroplasty, the expertise of the clinician(s), and the patient's preferences, also influence the surgical management.

The panel reviewed available published data on the surgical management of THA and TKA. Figures 1–3 show treatment algorithms for initial surgical management following these procedures that are based on published data and the panel's expert opinion. The final operative decision is up to the treating orthopedic surgeon after consultation with the patient.

Debridement without removal of the infected prosthesis can be done via either an open arthrotomy or arthroscopy [55–80]. Open arthrotomy allows for an extensive debridement and polyethylene liner exchange and is the most extensively described technique. There are increasing data that arthroscopy provides worse outcomes compared with open arthrotomy [62, 76]. Debridement of the infected prosthesis without removal of the prosthetic joint is associated with a success rate of 14%–100% [56–58, 60–62, 64, 66–74, 76–78, 81–84]. This surgical modality is typically reserved for patients with a well-fixed prosthesis with early postoperative PJI (<30 days) or patients with short duration of symptoms in hematogenous infection. There is an increased risk of treatment failure reported in patients with a sinus tract [2, 67] and infections due to certain organisms such as *S. aureus* when not treated with a rifampin combination [67], methicillin-resistant *S. (MRSA)*, and gram-negative organisms [85–90]. Treatment failure following debridement and retention includes meeting the definition of infection mentioned previously as well as persistent pain that is intolerable to the patient. Following an algorithmic approach seems to provide benefit in outcome and is encouraged by the panel, although different algorithms exist and individual judgment must be used in all situations [2, 80, 83, 85, 88, 91]. There have been recent reports suggesting there may be a worse outcome for 2-stage exchange procedures following a failed debridement and retention procedure. Further data on this are warranted to help clinicians

decide on the overall utility of the debridement and retention strategy [84, 92].

A 1-stage exchange or revision procedure involves excision of all prosthetic components and poly methyl methacrylate cement, debridement of devitalized bone and soft tissues, prosthesis removal, and implantation of a new prosthesis. This procedure is associated with a success rate of 80%–90% in patients with THA infection and its success is likely attributable to the extent of the debridement [93–95]. Most series use antibiotic impregnated cement to fix the new prosthesis [94, 96]. A recent decision analysis favored direct exchange over 2-stage exchange [95]. There are much fewer data for the use of this procedure for prosthetic joints other than a THA or without antibiotic impregnated cement and with bone graft [94, 97–99]. There is more literature on the utilization of this procedure from European than US institutions for THA infection. This difference may be owing to a low number of patients in the United States that are eligible for this type of procedure [100]. Published criteria for these procedures have included a relatively healthy patient with adequate bone stock and soft tissues, and patients with an easily treatable organism, which usually has been defined as streptococci other than enterococci, methicillin-sensitive staphylococci, and nonpseudomonal gram-negative organisms. Enterococci and fungal organisms, as well as infection due to small-colony variants, have been thought to be difficult to treat [2, 88, 94, 101]. The panel believes that the pathogen at a minimum should be susceptible to oral agents with excellent bioavailability. One-stage exchange is typically not recommended in patients with a sinus tract. Potential advantages of this single exchange procedure result from saving the patient and the healthcare system an additional surgery, and include lower morbidity rate and lower cost [91, 95].

Staged exchange or 2-stage exchange is most often used in the United States for the treatment of chronic PJI associated with prosthesis loosening [102–116]. This procedure is reported to have an overall incidence of success of 87% in a recent review [4]. This strategy involves removal of all infected prosthetic components and cement followed by debridement of infected periprosthetic tissue. Local antimicrobial-impregnated cement and devices are commonly used in the treatment of PJI. The antibiotic-impregnated cement is either premixed or mixed with an antimicrobial by the surgeon in the operating room. The clinician should be aware of the potential for systemic toxicity of local antimicrobial delivery devices, although this rarely occurs [112, 115]. Antimicrobial impregnated static or articulating spacers are often used to manage dead space and deliver local antimicrobial therapy until a permanent prosthesis is placed [108, 117]. Some panel members do not recommend spacers for MRSA infection, infection due to small-colony variants, or fungi as they believe that the use of spacers in these settings may be detrimental to the eradication

of infection (W. Z.) [2, 118]. Reports of successful use of spacers for MRSA PJI have been published [119]. The time from resection arthroplasty to reimplantation varies significantly from 2 weeks to several months. The use of antibiotic-impregnated cement and spacers has not been evaluated in randomized controlled trials [105, 108]. Systemic antimicrobials are administered following resection for 4–6 weeks in many centers (Table 2). Selected centers use the serum bactericidal test to guide proper dosing of antimicrobial therapy. None of the panel members have any experience using the serum bactericidal titer for this indication [120].

A delayed or second stage then occurs when a new prosthesis is reimplanted, weeks to months after resection arthroplasty, depending on the type of prosthesis. Both cemented and noncemented prostheses are utilized depending on the technical factors. The US Food and Drug Administration has approved several aminoglycoside-containing cements for fixation of the prosthesis at the time of reimplantation [107].

Ideal patients for this strategy are patients with chronic infections with adequate bone stock, who are medically fit and willing to undergo at least 2 surgeries [2, 4, 121–123]. Patients with sinus tracts or with difficult-to-treat organisms such as MRSA, enterococci, and *Candida* species would also potentially qualify for this procedure. In earlier cohort studies, early reimplantation within 3 weeks after resection resulted in a higher failure rate [110]. Cohort studies from Europe revealed a favorable outcome with reimplantation within 2–6 weeks while systemic antimicrobials are still being administered in selected situations when the infection is not due to MRSA, enterococci, multidrug-resistant gram-negative organisms [2]. Delayed reimplantation after 4–6 weeks of intravenous antimicrobial therapy and an antibiotic-free period of 2–8 weeks has been highly successful. This strategy is used frequently in the United States [13, 104, 106, 120]. The use of an articulating spacer may allow for a more extended antibiotic-free period without an effect on the functional outcome. More recent cases series describe a successful outcome with very short or no intravenous antimicrobial therapy when antimicrobial impregnated spacers are used, although the panel does not currently recommend this approach [109, 113]. Earlier reimplantation or the use of an articulating spacer may improve function, especially in the knee joint.

The period of time between resection arthroplasty and reimplantation can be used to evaluate for residual infection by clinical assessment and laboratory tests as well as intraoperative inspection and pathologic review of the periprosthetic tissue at the time of reimplantation. The panel does recommend obtaining a prerevision sedimentation rate and CRP to assess the success of treatment prior to reimplantation. Although recent studies suggest that a persistently elevated CRP level and sedimentation rate may not be accurate in predicting

persistent PJI after resection arthroplasty, the need for subsequent debridement must be interpreted in the context of the entire clinical picture when deciding timing of reimplantation [124–126]. Synovial fluid examination and joint aspirate cultures prior to reimplantation have been advocated by some investigators [125–127]. The panel did not endorse this testing in all patients but thought it could be used in selected cases when the clinician was concerned about persistent infection. In cases of suspected infection based on preoperative and intraoperative findings by the surgeon or a pathologist's review of periprosthetic tissue for acute inflammation at the time of delayed reimplantation, another debridement is typically performed [53]. If infection reoccurs again after a 2-stage exchange has been accomplished, the success rate with a second 2-stage exchange attempt may be lower than with the first attempt [102, 116, 128–130]. The panel believes, however, that in selected circumstances a second 2-stage exchange can be successful.

Permanent resection arthroplasty involves the resection of the infected prosthesis without reimplantation [94, 131–136]. After TKA resection, the knee may be arthrodesed to allow weight bearing. Arthrodesis can be accomplished with either an external fixator or intramedullary nail [137, 138]. Currently these procedures have limited indications. They have been utilized in nonambulatory patients; patients with limited bone stock, poor soft tissue coverage, or infections due to highly resistant organisms for which there is no or limited medical therapy; patients with a medical condition precluding major surgery; or patients who have failed 2-stage exchange in which the risk of recurrent infection after a staged exchange is deemed unacceptable. This procedure often is done in an effort to avoid amputation in ambulatory patients. It is usually followed by administration of 4–6 weeks of intravenous antimicrobials or highly bioavailable oral antimicrobials. Eradication of infection occurs in 60%–100% of cases, which is less than the reported efficacy of staged exchange. This difference of outcome may be due to selection bias.

Amputation may be required in selected cases such as the presence of necrotizing fasciitis not responding to debridement alone, severe bone loss, the inability or failure to achieve soft tissue coverage, or if a prior attempt at resection arthroplasty to control infection has failed [4, 139–142]. This procedure can also be considered if the patient's long-term functional outcome would be better with amputation rather than resection arthroplasty or arthrodesis (eg, some nonambulatory patients).

III. What is the medical treatment for a patient with PJI following debridement and retention of the prosthesis?

Recommendations

Staphylococcal PJI

23. Two to 6 weeks of a pathogen-specific intravenous antimicrobial therapy (Table 2) in combination with

rifampin 300–450 mg orally twice daily followed by rifampin plus a companion oral drug for a total of 3 months for a THA infection and 6 months for a TKA infection (A-I). Total elbow, total shoulder, and total ankle infections may be managed with the same protocols as THA infections (C-III). Recommended oral companion drugs for rifampin include ciprofloxacin (A-I) or levofloxacin (A-II). Secondary companion drugs to be used if in vitro susceptibility, allergies, intolerances, or potential intolerances support the use of an agent other than a quinolone include but are not limited to co-trimoxazole (A-II), minocycline or doxycycline (C-III), or oral first-generation cephalosporins (eg, cephalexin) or antistaphylococcal penicillins (eg, dicloxacillin; C-III). If rifampin cannot be used because of allergy, toxicity, or intolerance, the panel recommends 4–6 weeks of pathogen-specific intravenous antimicrobial therapy (B-III).

24. Monitoring of outpatient intravenous antimicrobial therapy should follow published guidelines (A-II) [6].

25. Indefinite chronic oral antimicrobial suppression may follow the above regimen with cephalexin, dicloxacillin, co-trimoxazole, or minocycline based on in vitro susceptibility, allergies, or intolerances (Table 3; B-III). Rifampin alone for chronic suppression is not recommended and rifampin combination therapy is also not generally recommended. One member of the panel uses rifampin combination therapy for chronic suppression in selected situations (A. R. B.). The recommendation regarding using suppressive therapy after rifampin treatment was not unanimous (W. Z., D. L.). Clinical and laboratory monitoring for efficacy and toxicity is advisable (Table 3). The decision to offer chronic suppressive therapy must take into account the individual circumstances of the patient including the ability to use rifampin in the initial phase of treatment, the potential for progressive implant loosening and loss of bone stock, and the hazards of prolonged antibiotic therapy; it is therefore generally reserved for patients who are unsuitable for, or refuse, further exchange revision, excision arthroplasty, or amputation.

PJI Due to Other Organisms

26. Four to 6 weeks of pathogen-specific intravenous or highly bioavailable oral antimicrobial therapy (Table 2; B-II).

27. Monitoring of outpatient intravenous antimicrobial therapy should follow published guidelines (A-II) [6].

28. Indefinite chronic oral antimicrobial suppression may follow the above regimens (Table 3) based on in vitro sensitivities, allergies, and intolerances (B-III). Chronic suppression after fluoroquinolone treatment of gram-negative bacilli was not unanimously recommended (W. Z., D. L.). Clinical and laboratory monitoring for efficacy and toxicity is advisable (Table 3).

Similar considerations regarding hazards and effectiveness apply to those above.

Evidence Summary

Following debridement and retention of staphylococcal PJI, the panel advocates the use of a combination of a β -lactam and vancomycin with rifampin for 2–6 weeks, assuming the organisms are susceptible in vitro to these antimicrobials and rifampin can be utilized safely (Table 2) [74, 78]. Rifampin should always be used in combination with other antimicrobials because of its activity against biofilm organisms and because of a high rate of emergence of resistance if used as monotherapy [2, 77, 143]. If the staphylococci are oxacillin susceptible, nafcillin, oxacillin, or cefazolin are appropriate intravenous companion drugs for rifampin. The use of ceftriaxone for oxacillin-susceptible staphylococci is discussed elsewhere (resection arthroplasty). If the isolate is oxacillin resistant, vancomycin is the primary companion drug of choice [78]. If the organism is resistant to both oxacillin and vancomycin, or if the patient is allergic or intolerant to these drugs, alternatives include daptomycin or linezolid [88, 144–148]. Although vancomycin has well-known potential toxicities including leukopenia, ototoxicity, and, rarely, nephrotoxicity, it must be remembered that linezolid has been associated with cytopenias, peripheral neuropathy, and optic neuritis and serotonin syndrome in patients treated concurrently with monoamine oxidase inhibitors or serotonin reuptake inhibitors and lactic acidosis [149–155]. Severe anemia may also be more common in patients with preexisting anemia prior to the use of linezolid [156]. In addition, one article has suggested that the concomitant use of rifampin may decrease levels of linezolid [150]. However, other authors have suggested that this combination is efficacious in humans and experimental models [147, 157]. There is even less published experience with daptomycin [158–163]. Monitoring for daptomycin toxicity including rhabdomyolysis, neuropathy, and eosinophilic pneumonia is important [6, 164]. It is recommended that statins be stopped, if possible, while administering daptomycin. Emergence of daptomycin resistance on therapy to daptomycin has occurred [163, 165]. Emergence of daptomycin resistance was not observed in a recent experimental model [158]. In addition, with daptomycin doses corresponding to 6 mg/kg in humans, no emergence of rifampin resistance was observed when both drugs were used in combination. For patients with nonstaphylococcal PJI treated with debridement and retention, the panel agrees on using an induction course of intravenous antimicrobial therapy or highly available oral therapy as outlined in Table 2 based on in vitro sensitivity testing. The use of quinolones after debridement and retention for susceptible aerobic gram-negative PJI may improve the outcome [166, 167].

The role of quinolone/rifampin combination in the treatment of staphylococcal orthopedic implant-related infection treated with debridement and component retention was analyzed in a single randomized clinical trial of susceptible staphylococcal infections of prosthetic joints and fracture fixation devices [78]. Although the intent-to-treat analysis did not show a statistically significant difference, there was a statistical benefit in using combination therapy with ciprofloxacin and rifampin in those patients who were able to complete therapy. A recent cohort also suggests excellent efficacy of the ciprofloxacin and rifampin combination [62]. Monitoring for adverse effects to quinolones (including but not limited to tendinopathy, prolonged QTc) and rifampin (hepatitis, significant drug interactions) as with all antimicrobials is vital. Cohort studies suggest that levofloxacin is also safe and effective in this setting and the improved in vitro antistaphylococcal activity may favor its use in susceptible isolates [168]. In patients with quinolone-resistant isolates, possible oral companion drugs for rifampin, assuming the organism is susceptible in vitro, can include co-trimoxazole, minocycline or doxycycline, or oral first-generation cephalosporins such as cephalexin. Fusidic acid as a companion drug has been used in Europe [57]. The oral companion drug/rifampin combination is utilized to complete a total of 3–6 months (3 months for THA PJI and 6 months for TKA PJI).

Chronic Oral Antimicrobial Suppression

The panel could not agree on the use and duration of chronic suppression following the induction course of intravenous antimicrobial therapy in nonstaphylococcal PJI or following the 3- to 6-month course of quinolone or other companion drug/rifampin in staphylococcal PJI treated with debridement and component retention. Some members of the panel (D. L., W. Z.) would never use chronic suppression after rifampin combination therapy; others would recommend the use of chronic suppression in all cases of PJI treated with debridement and component retention, assuming the patient tolerates the medication without difficulty, whereas others would use it selectively in elderly or immunosuppressed patients, patients with a staphylococcal PJI in which rifampin is not utilized, elderly patients with nonstaphylococcal PJI, or patients whose comorbidities would not allow additional surgery or in whom additional surgery may be limb-threatening in case of treatment failure. Rifampin alone and linezolid should not be used for indefinite chronic suppression. Rifampin combination therapy is also not generally recommended; one member of the panel uses rifampin combination therapy for chronic suppression in selected situations (A. R. B.) [62]. Table 3 summarizes the antimicrobials that are commonly used for chronic suppression [81, 169–171].

If chronic oral suppression is not utilized or discontinued, recent data would suggest that there is a 4-fold increased risk

of treatment failure at the time suppression is discontinued, and that this risk of failure is greatest in the 4 months following antimicrobial discontinuation [62]. However, in this study the majority of patients who had their chronic suppression discontinued did not suffer treatment failure, suggesting that many patients are cured without the use of chronic suppression but that defining that group of patients can be difficult [62]. Thus if this pathway is chosen, monitoring for treatment failure early after treatment discontinuation is chosen is important. The investigators of this study also pointed out that the vast majority of their study patients received at least 6 months of intravenous or oral antimicrobial therapy. Recommending the use of chronic suppression in young patients is particularly controversial and must be done on a case-by-case basis. It is advisable that patients on chronic oral antimicrobial suppression be monitored both for clinical failure and for antimicrobial toxicity (Table 3).

IV. What is the medical treatment for a patient with PJI following resection arthroplasty with or without planned staged reimplantation?

Recommendations

29. Four to 6 weeks of pathogen-specific intravenous or highly bioavailable oral antimicrobial therapy is recommended (Table 2; **A-II**).

30. Monitoring of outpatient intravenous antimicrobial therapy should follow published guidelines (**A-II**) [6].

Evidence Summary

In the United States, patients undergoing resection arthroplasty typically receive 4–6 weeks of intravenous or highly bioavailable oral antimicrobial therapy between resection arthroplasty and reimplantation [13, 14, 104]. Most panel members would use 6 weeks of therapy for more virulent organisms such as *S. aureus*. Specific recommended antimicrobials are delineated in Table 2. Cefazolin or nafcillin is recommended for oxacillin-sensitive staphylococci and vancomycin for MRSA [2, 88, 104]. There was not a consensus on the use of ceftriaxone as a single agent for oxacillin-susceptible staphylococcal infections. The panel recognizes that there are retrospective cohort data with short duration of follow-up available to support its use in bone and joint infections and PJI due to oxacillin-susceptible staphylococci [172–174]. Rifampin is not routinely recommended as a companion drug in this situation as all foreign material has been removed and there are no clinical data supporting the need for a biofilm active agent in this setting, while the risk of rifampin toxicity is not minimal. In patients undergoing 2-stage exchange, no antimicrobial therapy should be used prior to planned resection arthroplasty until tissue cultures or ultrasonicate fluid cultures have been obtained, in order to improve the diagnostic

yield of tissue cultures or ultrasonicate. However, prophylaxis according to standard guidelines to prevent surgical site infection at the time of total joint arthroplasty should be used prior to reimplantation arthroplasty if it is believed the prior PJI has been eradicated.

V. What is the medical treatment for a patient with PJI following 1-stage exchange?

Recommendations

Staphylococcal PJI

31. Two to 6 weeks of pathogen-specific intravenous antimicrobial therapy in combination with rifampin 300–450 mg orally twice daily followed by rifampin plus a companion oral drug for a total of 3 months is recommended (Table 2; **C-III**). Recommended oral companion drugs for rifampin include ciprofloxacin (**A-I**) or levofloxacin (**A-II**). Secondary companion drugs to be used if in vitro susceptibility, allergies, intolerances, or potential intolerances support the use of an agent other than a quinolone include but are not limited to co-trimoxazole (**A-II**), minocycline or doxycycline (**B-III**), or oral first-generation cephalosporins (eg, cephalexin) or antistaphylococcal penicillins (eg, dicloxacillin; **C-III**). If rifampin cannot be used because of allergy, toxicity, or intolerance then the panel recommends 4–6 weeks of pathogen-specific intravenous antimicrobial therapy.

32. Monitoring of outpatient intravenous antimicrobial therapy should follow published guidelines (**A-II**) [6].

33. Indefinite chronic oral antimicrobial suppression may follow the above regimen with either cephalexin, dicloxacillin, co-trimoxazole, or minocycline or doxycycline based on in vitro susceptibility, allergies, or intolerances (Table 3; **B-III**). Rifampin alone is not recommended for chronic suppression, and rifampin combination therapy is also not generally recommended. One member of the panel uses rifampin combination therapy for chronic suppression in selected situations (A. R. B.). The recommendation regarding using suppressive therapy after rifampin treatment was not unanimous (D. L., W. Z.). Clinical and laboratory monitoring for efficacy and toxicity is advisable. The decision to offer chronic suppressive therapy must take into account the individual circumstances of the patient including the ability to use rifampin in the initial phase of treatment, the potential for progressive implant loosening and loss of bone stock, and the hazards of prolonged antibiotic therapy; it is therefore generally reserved for patients who are unsuitable for, or refuse, further exchange revision, excision arthroplasty, or amputation.

PJI Due to Other Organisms

34. Four to 6 weeks of pathogen-specific intravenous or highly bioavailable oral antimicrobial therapy is recommended (Table 2; **A-II**).

35. Monitoring of outpatient intravenous antimicrobial therapy should follow published guidelines (**A-II**) [6].

36. Indefinite chronic oral antimicrobial suppression should follow regimens in Table 3 and be based on in vitro sensitivities, allergies, and intolerances (**B-III**). Chronic suppression after fluoroquinolone treatment of gram-negative bacilli was not unanimously recommended (D. L., W. Z.). Clinical and laboratory monitoring for efficacy and toxicity is advisable. Similar considerations regarding hazards and effectiveness apply to those above.

Evidence Summary

There are 2 ways a 1-stage exchange can be performed. One involves purposefully planning to do a 1-stage exchange, identifying the pathogen preoperatively followed by 4–6 weeks of pathogen-directed intravenous or highly bioavailable oral antimicrobial therapy following the exchange procedure, with or without the use of chronic oral antimicrobial suppression (Table 2) [14, 101]. A second method, a 1-stage exchange, is inadvertently due to the fact that a revision surgery performed for presumed aseptic loosening occurs, and after surgery a diagnosis of PJI is confirmed by multiple positive cultures yielding the same organism [13, 14, 175]. This strategy is reported to have a success rate of 80%–100%. A biofilm active agent for susceptible staphylococcal infections can be used with a regimen similar to THA infection treated with debridement and retention, although there are no specific clinical data to support rifampin combinations in this setting. Other retrospective studies have used chronic oral suppression with success [175]. Most members of the panel supported the use of chronic oral suppression to prevent relapse of infection (Table 3). The decision to offer chronic suppressive therapy must take into account the individual circumstances of the patient including the ability to use rifampin, the potential for progressive implant loosening and loss of bone stock, and the hazards of prolonged antibiotic therapy; it is therefore generally reserved for patients who are unsuitable for, or refuse, further exchange revision, excision arthroplasty, or amputation. Rifampin alone and linezolid should not be used for indefinite chronic suppression. Rifampin combination therapy is also not generally recommended, although 1 member of the panel uses rifampin combination therapy for chronic suppression in selected situations (A. R. B.) [62].

An approach described by French investigators involves pretreating patients with up to 6 months of a rifampin-containing oral regimen prior to a 1-stage exchange [66, 71]. This approach has the possible disadvantage of the patient having a potentially painful loose prosthesis while having medical therapy.

VI. What is the medical treatment for a patient with PJI following amputation?

37. Pathogen-specific antimicrobial therapy should be given until 24–48 hours after amputation assuming all infected bone and soft tissue has been surgically amputated and there is no concomitant sepsis syndrome or bacteremia. If sepsis syndrome or bacteremia are present, treatment duration is to be according to recommendations for these syndromes (C-III).

38. Four to 6 weeks of pathogen-specific intravenous or highly bioavailable oral antimicrobial therapy is recommended if, despite surgery, there is residual infected bone and soft tissue (ie, hip disarticulation for THA infection, long-stem TKA prosthesis where the prosthesis extended above the level of amputation; Table 2; C-III).

39. Monitoring of outpatient intravenous antimicrobial therapy should follow published guidelines (A-II) [6].

Evidence Summary

Data for these recommendations are based on the expert opinion of the investigators and extrapolated data from data for staged exchange. Pathogen-specific antimicrobial therapy following amputation should be given until 24–48 hours assuming all infected bone and soft tissue have been surgically removed and there is no concomitant sepsis syndrome or bacteremia. If sepsis syndrome or bacteremia is present, treatment duration should be according to recommendations for these syndromes. Four to 6 weeks of pathogen-specific intravenous or highly bioavailable oral antimicrobial therapy is recommended if there is residual infected bone (ie, hip disarticulation for THA infection, long-stem TKA prosthesis where the prosthesis extended above the level of amputation) as would be recommended for chronic osteomyelitis. Monitoring of outpatient intravenous antimicrobial therapy should follow published guidelines [6].

RESEARCH GAPS

The initial step in developing a rational clinical research agenda is the identification of gaps in information. The process of guideline development, as practiced by IDSA, serves as a natural means by which such gaps are identified. Thus, the guidelines identify important clinical questions and identify the quality of evidence supporting those recommendations. Clinical questions identified by guideline authors and members of the IDSA Research Committee and SPGC that could inform a research agenda for the diagnosis and management of PJI are included below.

Epidemiology

What is the incidence rate of PJI in patients who undergo different types of joint arthroplasty and what are the risk factors that predispose patients to PJI? What type of database and

epidemiologic information would be useful for future studies to improve the diagnosis and management of PJI (eg, national registry)?

Diagnostics

Can rapid methodologies, such as polymerase chain reaction, be used to optimally identify pathogens causing PJI? What is the role of prosthesis sonication and beadmill processing in the diagnosis of PJI? Is there an optimal incubation time to recover biofilm organisms? What is the role of inflammatory biomarkers in synovial fluid and serum in the diagnosis of PJI? What are the best molecular, radiographic, and culturing methods for diagnosing PJI?

Management

What are the optimal and most cost-effective algorithms of surgical and medical treatment strategies for the management of PJI? What is the efficacy of oral vs parenteral therapy, or oral step-down therapy as an alternative to prolonged parenteral therapy? What is the efficacy of rifampin combination therapy for staphylococcal PJI? What are alternatives to vancomycin for the management of infection with MRSA or coagulase-negative *Staphylococcus*? What is the role of chronic suppression, where is it indicated, and how much is adequate? Which agents are appropriate for suppression?

When is it appropriate to perform 1-stage vs 2-stage reimplantation? When is the appropriate time to reimplant when using a 2-stage exchange? What factors, including demographics, microbiology, serum inflammatory markers, and imaging studies, are useful in predicting the outcome of PJI?

Prevention

What is the role of antibiotic prophylaxis in patients undergoing dental procedures or invasive (gastrointestinal, genitourinary) procedures? What is the role of *S. aureus* screening and decolonization with mupirocin and/or chlorhexidine bathing prior to surgery? How does higher oxygen therapy administered in the operating room impact the prevention of PJI? What roles do operative markers such as hypothermia and blood transfusion play in preventing PJI?

Notes

Acknowledgments. The panel wishes to express its gratitude to Drs Barry D. Brause and Paul Pottinger for their thoughtful reviews of an earlier draft of the guideline. In addition, the panel recognizes the following individuals for their important contributions in identifying critical gaps where funding of research is needed to advance clinical treatment and care: Carol A. Kauffman, MD, and Debra D. Poutsiaka, MD, PhD (Infectious Diseases Society of America [IDSA] Research Committee); Steven D. Burdette, MD (IDSA Standards and Practice Guidelines Committee); Tad M. Mabry, MD (Orthopedic Surgical Advisor); and Padma Natarajan (IDSA staff).

Financial support. This work was supported by the Infectious Diseases Society of America.

Potential conflicts of interest. The following list is a reflection of what has been reported to IDSA. In order to provide thorough transparency, IDSA requires full disclosure of all relationships, regardless of relevancy to the guideline topic. The reader of these guidelines should be mindful of this when the list of disclosures is reviewed.

D. O. has received research grants from Cubist Pharmaceuticals and Ortho-McNeil. E. B. has received funding from Cubist Pharmaceuticals, Ortho McNeil, Orthopedic Research, and Education Foundation and Mayo. A. H. has received royalties from Stryker Corp for hip/knee design. W. Z. has served as a board member of Pfizer and on the speakers' bureaus of Pfizer and Synthes, Inc. D. L. is a member of the Board of Basilea. A. B. was awarded a Pfizer Visiting Professorship to the Department of Allergy and Infectious Diseases at the University of Washington, Seattle. All other authors report no potential conflicts.

All authors have submitted the ICMJE Form for Disclosure of Potential Conflicts of Interest. Conflicts that the editors consider relevant to the content of the manuscript have been disclosed.

References

- Steckelberg JM, Osmon DR. Prosthetic joint infections. In: Waldvogel FAB, Bisno AL, eds. *Infections associated with indwelling medical devices*. 3rd ed. Washington, DC: American Society for Microbiology, 2000:173–209.
- Zimmerli W, Trampuz A, Ochsner PE. Prosthetic-joint infections. *N Engl J Med* 2004; 351:1645–54.
- Darouiche RO. Treatment of infections associated with surgical implants. *N Engl J Med* 2004; 350:1422–9.
- Sia IG, Berbari EF, Karchmer AW. Prosthetic joint infections. *Infect Dis Clin North Am* 2005; 19:885–914.
- Canadian Task Force on the Periodic Health Examination. The periodic health examination. Canadian Task Force on the Periodic Health Examination. *Can Med Assoc J* 1979; 121:1193–254.
- Tice AD, Rehm SJ, Dalovisio JR, et al. Practice guidelines for outpatient parenteral antimicrobial therapy. IDSA guidelines. *Clin Infect Dis* 2004; 38:1651–72.
- National Center for Health Statistics. National Hospital Discharge Survey: 2004 annual summary with detailed diagnosis and procedure data. National Center for Health Statistics, 2009. Available at: <http://www.cdc.gov/nchs/fastats/insurg.htm>. Accessed June 2012.
- Lentino JR. Prosthetic joint infections: bane of orthopedists, challenge for infectious disease specialists. *Clin Infect Dis* 2003; 36:1157–61.
- Lidgren L, Knutson K, Stefansdottir A. Infection and arthritis. Infection of prosthetic joints. *Best Pract Res Clin Rheumatol* 2003; 17:209–18.
- Hanssen AD, Rand JA. Evaluation and treatment of infection at the site of a total hip or knee arthroplasty. *Instr Course Lect* 1999; 48:111–22.
- Kurtz S, Ong K, Lau E, Mowat F, Halpern M. Projections of primary and revision hip and knee arthroplasty in the United States from 2005 to 2030. *J Bone Joint Surg Am* 2007; 89:780–5.
- Field MJ, Lohr KN; Institute of Medicine Committee to Advise the Public Health Service on Clinical Practice Guidelines. *Clinical Practice Guidelines: directions for a new program*. Washington, DC: National Academies Press, 1990:52–77.
- Segawa H, Tsukayama DT, Kyle RF, Becker DA, Gustilo RB. Infection after total knee arthroplasty. A retrospective study of the treatment of eighty-one infections. *J Bone Joint Surg Am* 1999; 81:1434–45.
- Tsukayama DT, Estrada R, Gustilo RB. Infection after total hip arthroplasty. A study of the treatment of one hundred and six infections. *J Bone Joint Surg Am* 1996; 78:512–23.
- Zimmerli W. Infection and musculoskeletal conditions: prosthetic-joint-associated infections. *Best Pract Res Clin Rheumatol* 2006; 20:1045–63.
- Deacon JM, Pagliaro AJ, Zelicof SB, Horowitz HW. Prophylactic use of antibiotics for procedures after total joint replacement. *J Bone Joint Surg Am* 1996; 78:1755–70.
- Maderazo EG, Judson S, Pasternak H. Late infections of total joint prostheses. A review and recommendations for prevention. *Clin Orthop Relat Res* 1988; 131–42.
- Sendi P, Banderet F, Graber P, Zimmerli W. Clinical comparison between exogenous and haematogenous periprosthetic joint infections caused by *Staphylococcus aureus*. *Clin Microbiol Infect* 2011; 17:1098–100.
- Patel R, Osmon DR, Hanssen AD. The diagnosis of prosthetic joint infection: current techniques and emerging technologies. *Clin Orthop Relat Res* 2005; 55–8.
- Berbari EF, Marculescu C, Sia I, et al. Culture-negative prosthetic joint infection. *Clin Infect Dis* 2007; 45:1113–9.
- Spanghehl MJ, Masri BA, O'Connell JX, Duncan CP. Prospective analysis of preoperative and intraoperative investigations for the diagnosis of infection at the sites of two hundred and two revision total hip arthroplasties. *J Bone Joint Surg Am* 1999; 81:672–83.
- Parvizi J, Ghanem E, Menashe S, Barrack RL, Bauer TW. Periprosthetic infection: what are the diagnostic challenges? *J Bone Joint Surg Am* 2006; 88(suppl 4):138–47.
- Sampedro MF, Patel R. Infections associated with long-term prosthetic devices. *Infect Dis Clin North Am* 2007; 21:785–819, x.
- Cuckler JM, Star AM, Alavi A, Noto RB. Diagnosis and management of the infected total joint arthroplasty. *Orthop Clin North Am* 1991; 22:523–30.
- Bernard L, Lubbeke A, Stern R, et al. Value of preoperative investigations in diagnosing prosthetic joint infection: retrospective cohort study and literature review. *Scand J Infect Dis* 2004; 36:410–6.
- Berbari E, Mabry T, Tsaras G, et al. Inflammatory blood laboratory levels as markers of prosthetic joint infection: a systematic review and meta-analysis. *J Bone Joint Surg Am* 2010; 92:2102–9.
- Bedair H, Ting N, Jacovides C, et al. The Mark Coventry Award: diagnosis of early postoperative TKA infection using synovial fluid analysis. *Clin Orthop Relat Res* 2011; 469:34–40.
- Greidanus NV, Masri BA, Garbuz DS, et al. Use of erythrocyte sedimentation rate and C-reactive protein level to diagnose infection before revision total knee arthroplasty. A prospective evaluation. *J Bone Joint Surg Am* 2007; 89:1409–16.
- Austin MS, Ghanem E, Joshi A, Lindsay A, Parvizi J. A simple, cost-effective screening protocol to rule out periprosthetic infection. *J Arthroplasty* 2008; 23:65–8.
- American Academy of Orthopaedic Surgeons. The diagnosis of periprosthetic joint infections of the hip and knee: guideline and evidence report. Rosemont, IL: American Academy of Orthopaedic Surgeons; 2010.
- Bottner F, Wegner A, Winkelmann W, Becker K, Erren M, Gotze C. Interleukin-6, procalcitonin and TNF-alpha: markers of periprosthetic infection following total joint replacement. *J Bone Joint Surg Br* 2007; 89:94–9.
- Buttaro MA, Tanoira I, Comba F, Piccaluga F. Combining C-reactive protein and interleukin-6 may be useful to detect periprosthetic hip infection. *Clin Orthop Relat Res* 2010; 468:3263–7.
- Barrack RL. The value of preoperative knee aspiration: don't ask, don't tell. *Orthopedics* 1997; 20:862–4.
- Trampuz A, Hanssen AD, Osmon DR, Mandrekar J, Steckelberg JM, Patel R. Synovial fluid leukocyte count and differential for the diagnosis of prosthetic knee infection. *Am J Med* 2004; 117:556–62.
- Schinsky MF, Della Valle CJ, Sporer SM, Papprosky WG. Perioperative testing for joint infection in patients undergoing revision total hip arthroplasty. *J Bone Joint Surg Am* 2008; 90:1869–75.
- Pandey R, Berend AR, Athanasou NA. Histological and microbiological findings in non-infected and infected revision arthroplasty tissues. The OSIRIS Collaborative Study Group. Oxford Skeletal Infection Research and Intervention Service. *Arch Orthop Trauma Surg* 2000; 120:570–4.

37. Pace TB, Jeray KJ, Latham JT Jr. Synovial tissue examination by frozen section as an indicator of infection in hip and knee arthroplasty in community hospitals. *J Arthroplasty* **1997**; 12:64–9.
38. Lonner JH, Desai P, Dicesare PE, Steiner G, Zuckerman JD. The reliability of analysis of intraoperative frozen sections for identifying active infection during revision hip or knee arthroplasty. *J Bone Joint Surg Am* **1996**; 78:1553–8.
39. Bori G, Soriano A, Garcia S, Gallart X, Mallofre C, Mensa J. Neutrophils in frozen section and type of microorganism isolated at the time of resection arthroplasty for the treatment of infection. *Arch Orthop Trauma Surg* **2009**; 129:591–5.
40. Atkins BL, Athanasou N, Deeks JJ, et al. Prospective evaluation of criteria for microbiological diagnosis of prosthetic-joint infection at revision arthroplasty. The OSIRIS Collaborative Study Group. *J Clin Microbiol* **1998**; 36:2932–9.
41. Trampuz A, Piper KE, Jacobson MJ, et al. Sonication of removed hip and knee prostheses for diagnosis of infection. *N Engl J Med* **2007**; 357:654–63.
42. Schafer P, Fink B, Sandow D, Margull A, Berger I, Frommelt L. Prolonged bacterial culture to identify late periprosthetic joint infection: a promising strategy. *Clin Infect Dis* **2008**; 47:1403–9.
43. Roux AL, Sivadon-Tardy V, Bauer T, et al. Diagnosis of prosthetic joint infection by beadmill processing of a periprosthetic specimen. *Clin Microbiol Infect* **2011**; 17:447–50.
44. Holinka J, Bauer L, Hirschl AM, Graninger W, Windhager R, Presterl E. Sonication cultures of explanted components as an add-on test to routinely conducted microbiological diagnostics improve pathogen detection. *J Orthop Res* **2011**; 29:617–22.
45. Morgan PM, Sharkey P, Ghanem E, et al. The value of intraoperative Gram stain in revision total knee arthroplasty. *J Bone Joint Surg Am* **2009**; 91:2124–9.
46. Johnson AJ, Zywiol MG, Stroh DA, Marker DR, Mont MA. Should Gram stains have a role in diagnosing hip arthroplasty infections? *Clin Orthop Relat Res* **2010**; 468:2387–91.
47. Oethinger M, Warner DK, Schindler SA, Kobayashi H, Bauer TW. Diagnosing periprosthetic infection: false-positive intraoperative Gram stains. *Clin Orthop Relat Res* **2011**; 469:954–60.
48. Trampuz A, Osmon DR, Hanssen AD, Steckelberg JM, Patel R. Molecular and antibiofilm approaches to prosthetic joint infection. *Clin Orthop Relat Res* **2003**; 69–88.
49. Tunney MM, Patrick S, Curran MD, et al. Detection of prosthetic hip infection at revision arthroplasty by immunofluorescence microscopy and PCR amplification of the bacterial 16S rRNA gene. *J Clin Microbiol* **1999**; 37:3281–90.
50. Tunney MM, Patrick S, Gorman SP, et al. Improved detection of infection in hip replacements. A currently underestimated problem. *J Bone Joint Surg Br* **1998**; 80:568–72.
51. Osmon DR, Hanssen AD, Patel R. Prosthetic joint infection: criteria for future definitions. *Clin Orthop Relat Res* **2005**; 89–90.
52. Browne JA, Bechtold CD, Berry DJ, Hanssen AD, Lewallen DG. Failed metal-on-metal hip arthroplasties: a spectrum of clinical presentations and operative findings. *Clin Orthop Relat Res* **2010**; 468:2313–20.
53. Della Valle CJ, Bogner E, Desai P, et al. Analysis of frozen sections of intraoperative specimens obtained at the time of reoperation after hip or knee resection arthroplasty for the treatment of infection. *J Bone Joint Surg Am* **1999**; 81:684–9.
54. Garvin KL, Hanssen AD. Infection after total hip arthroplasty. Past, present, and future. *J Bone Joint Surg Am* **1995**; 77:1576–88.
55. Fisman DN, Reilly DT, Karchmer AW, Goldie SJ. Clinical effectiveness and cost-effectiveness of 2 management strategies for infected total hip arthroplasty in the elderly. *Clin Infect Dis* **2001**; 32:419–30.
56. Meehan AM, Osmon DR, Duffy MC, Hanssen AD, Keating MR. Outcome of penicillin-susceptible streptococcal prosthetic joint infection treated with debridement and retention of the prosthesis. *Clin Infect Dis* **2003**; 36:845–9.
57. Aboltins CA, Page MA, Buising KL, et al. Treatment of staphylococcal prosthetic joint infections with debridement, prosthesis retention and oral rifampicin and fusidic acid. *Clin Microbiol Infect* **2007**; 13:586–91.
58. Barberan J. Management of infections of osteoarticular prosthesis. *Clin Microbiol Infect* **2006**; 12(suppl 3):93–101.
59. Berdal JE, Skramm I, Mowinckel P, Gulbrandsen P, Bjornholt JV. Use of rifampicin and ciprofloxacin combination therapy after surgical debridement in the treatment of early manifestation prosthetic joint infections. *Clin Microbiol Infect* **2005**; 11:843–5.
60. Brandt CM, Sistrunk WW, Duffy MC, et al. *Staphylococcus aureus* prosthetic joint infection treated with debridement and prosthesis retention. *Clin Infect Dis* **1997**; 24:914–9.
61. Burger RR, Basch T, Hopson CN. Implant salvage in infected total knee arthroplasty. *Clin Orthop Relat Res* **1991**; 105–12.
62. Byren I, Bejon P, Atkins BL, et al. One hundred and twelve infected arthroplasties treated with 'DAIR' (debridement, antibiotics and implant retention): antibiotic duration and outcome. *J Antimicrob Chemother* **2009**; 63:1264–71.
63. Choong PF, Dowsey MM, Carr D, Daffy J, Stanley P. Risk factors associated with acute hip prosthetic joint infections and outcome of treatment with a rifampin based regimen. *Acta Orthop* **2007**; 78:755–65.
64. Crockarell JR, Hanssen AD, Osmon DR, Morrey BF. Treatment of infection with debridement and retention of the components following hip arthroplasty. *J Bone Joint Surg Am* **1998**; 80:1306–13.
65. Deirmengian C, Greenbaum J, Lotke PA, Booth RE Jr, Lonner JH. Limited success with open debridement and retention of components in the treatment of acute *Staphylococcus aureus* infections after total knee arthroplasty. *J Arthroplasty* **2003**; 18:22–6.
66. Drancourt M, Stein A, Argenson JN, Zannier A, Curvale G, Raoult D. Oral rifampin plus ofloxacin for treatment of *Staphylococcus*-infected orthopedic implants. *Antimicrob Agents Chemother* **1993**; 37:1214–8.
67. Marculescu CE, Berbari EF, Hanssen AD, et al. Outcome of prosthetic joint infections treated with debridement and retention of components. *Clin Infect Dis* **2006**; 42:471–8.
68. Rasul AT Jr, Tsukayama D, Gustilo RB. Effect of time of onset and depth of infection on the outcome of total knee arthroplasty infections. *Clin Orthop Relat Res* **1991**; 98–104.
69. Schoifet SD, Morrey BF. Treatment of infection after total knee arthroplasty with debridement with retention of the components. *J Bone Joint Surg Am* **1990**; 72:1383–90.
70. Soriano A, Garcia S, Ortega M, et al. Treatment of acute infection of total or partial hip arthroplasty with debridement and oral chemotherapy. *Med Clin (Barc)* **2003**; 121:81–5.
71. Stein A, Bataille JF, Drancourt M, et al. Ambulatory treatment of multidrug-resistant *Staphylococcus*-infected orthopedic implants with high-dose oral co-trimoxazole (trimethoprim-sulfamethoxazole). *Antimicrob Agents Chemother* **1998**; 42:3086–91.
72. Tattevin P, Cremieux AC, Pottier P, Hutten D, Carbon C. Prosthetic joint infection: when can prosthesis salvage be considered? *Clin Infect Dis* **1999**; 29:292–5.
73. Teeny SM, Dorr L, Murata G, Conaty P. Treatment of infected total knee arthroplasty. Irrigation and debridement versus two-stage reimplantation. *J Arthroplasty* **1990**; 5:35–9.
74. Trebbe R, Pisot V, Trampuz A. Treatment of infected retained implants. *J Bone Joint Surg Br* **2005**; 87:249–56.
75. Waagsbo B, Sundoy A, Martinsen TM, Nymo LS. Treatment results with debridement and retention of infected hip prostheses. *Scand J Infect Dis* **2009**; 41:563–8.
76. Waldman BJ, Hosten E, Mont MA, Hungerford DS. Infected total knee arthroplasty treated by arthroscopic irrigation and debridement. *J Arthroplasty* **2000**; 15:430–6.

77. Widmer AF, Gaechter A, Ochsner PE, Zimmerli W. Antimicrobial treatment of orthopedic implant-related infections with rifampin combinations. *Clin Infect Dis* **1992**; 14:1251–3.
78. Zimmerli W, Widmer AF, Blatter M, Frei R, Ochsner PE. Role of rifampin for treatment of orthopedic implant-related staphylococcal infections: a randomized controlled trial. *Foreign-Body Infection (FBI) Study Group. JAMA* **1998**; 279:1537–41.
79. Muller-Serieys C, Saleh Mghir A, Massias L, Fantin B. Bactericidal activity of the combination of levofloxacin with rifampin in experimental prosthetic knee infection in rabbits due to methicillin-susceptible *Staphylococcus aureus*. *Antimicrob Agents Chemother* **2009**; 53:2145–8.
80. Giulieri SG, Graber P, Ochsner PE, Zimmerli W. Management of infection associated with total hip arthroplasty according to a treatment algorithm. *Infection* **2004**; 32:222–8.
81. Segreti J, Nelson JA, Trenholme GM. Prolonged suppressive antibiotic therapy for infected orthopedic prostheses. *Clin Infect Dis* **1998**; 27:711–3.
82. Choi HR, von Knoch F, Zurakowski D, Nelson SB, Malchau H. Can implant retention be recommended for treatment of infected TKA? *Clin Orthop Relat Res* **2011**; 469:961–9.
83. Kim YH, Choi Y, Kim JS. Treatment based on the type of infected TKA improves infection control. *Clin Orthop Relat Res* **2011**; 469:977–84.
84. Gardner J, Gioe TJ, Tatman P. Can this prosthesis be saved? Implant salvage attempts in infected primary TKA. *Clin Orthop Relat Res* **2011**; 469:970–6.
85. Betsch BY, Egli S, Siebenrock KA, Tauber MG, Muhlemann K. Treatment of joint prosthesis infection in accordance with current recommendations improves outcome. *Clin Infect Dis* **2008**; 46:1221–6.
86. Salgado CD, Dash S, Cantey JR, Marculescu CE. Higher risk of failure of methicillin-resistant *Staphylococcus aureus* prosthetic joint infections. *Clin Orthop Relat Res* **2007**; 461:48–53.
87. Bradbury T, Fehring TK, Taunton M, et al. The fate of acute methicillin-resistant *Staphylococcus aureus* periprosthetic knee infections treated by open debridement and retention of components. *J Arthroplasty* **2009**; 24:101–4.
88. Leone S, Borre S, Monforte A, et al. Consensus document on controversial issues in the diagnosis and treatment of prosthetic joint infections. *Int J Infect Dis* **2010**; 14(suppl 4):S67–77.
89. Hsieh PH, Lee MS, Hsu KY, Chang YH, Shih HN, Ueng SW. Gram-negative prosthetic joint infections: risk factors and outcome of treatment. *Clin Infect Dis* **2009**; 49:1036–43.
90. Uckay I, Bernard L. Gram-negative versus gram-positive prosthetic joint infections. *Clin Infect Dis* **2010**; 50:795.
91. De Man FH, Sendi P, Zimmerli W, Maurer TB, Ochsner PE, Ilchmann T. Infectiological, functional, and radiographic outcome after revision for prosthetic hip infection according to a strict algorithm. *Acta Orthopaedica* **2011**; 82:27–34.
92. Sherrell JC, Fehring TK, Odum S, et al. The Chitranjan Ranawat Award: fate of two-stage reimplantation after failed irrigation and debridement for periprosthetic knee infection. *Clin Orthop Relat Res* **2011**; 469:18–25.
93. Carlsson AS, Josefsson G, Lindberg L. Revision with gentamicin-impregnated cement for deep infections in total hip arthroplasties. *J Bone Joint Surg Am* **1978**; 60:1059–64.
94. Senthil S, Munro JT, Pitto RP. Infection in total hip replacement: meta-analysis. *Int Orthop* **2011**; 35:253–60.
95. Wolf CE, Gu NY, Doctor JN, Manner PA, Leopold SS. Comparison of one and two-stage revision of total hip arthroplasty complicated by infection: a Markov expected-utility decision analysis. *J Bone Joint Surg Am* **2011**; 93:631–9.
96. Jackson WO, Schmalzried TP. Limited role of direct exchange arthroplasty in the treatment of infected total hip replacements. *Clin Orthop Relat Res* **2000**; 101–5.
97. Jansen E, Stogiannidis I, Malmivaara A, Pajamaki J, Puolakka T, Kontinen YT. Outcome of prosthesis exchange for infected knee arthroplasty: the effect of treatment approach. *Acta Orthop* **2009**; 80:67–77.
98. Winkler H, Stoiber A, Kaudela K, Winter F, Menschik F. One stage uncemented revision of infected total hip replacement using cancellous allograft bone impregnated with antibiotics. *J Bone Joint Surg Br* **2008**; 90:1580–4.
99. Parkinson RW, Kay PR, Rawal A. A case for one-stage revision in infected total knee arthroplasty? *Knee* **2011**; 18:1–4.
100. Hanssen AD, Osmon DR. Assessment of patient selection criteria for treatment of the infected hip arthroplasty. *Clin Orthop Relat Res* **2000**; 91–100.
101. Ure KJ, Amstutz HC, Nasser S, Schmalzried TP. Direct-exchange arthroplasty for the treatment of infection after total hip replacement. An average ten-year follow-up. *J Bone Joint Surg Am* **1998**; 80:961–8.
102. Bejon P, Berendt A, Atkins BL, et al. Two-stage revision for prosthetic joint infection: predictors of outcome and the role of reimplantation microbiology. *J Antimicrob Chemother* **2010**; 65:569–75.
103. Biring GS, Kostamo T, Garbuz DS, Masri BA, Duncan CP. Two-stage revision arthroplasty of the hip for infection using an interim articulated Prostalac hip spacer: a 10- to 15-year follow-up study. *J Bone Joint Surg Br* **2009**; 91:1431–7.
104. Brandt CM, Duffy MC, Berbari EF, Hanssen AD, Steckelberg JM, Osmon DR. *Staphylococcus aureus* prosthetic joint infection treated with prosthesis removal and delayed reimplantation arthroplasty. *Mayo Clin Proc* **1999**; 74:553–8.
105. Cui Q, Mihalko WM, Shields JS, Ries M, Saleh KJ. Antibiotic-impregnated cement spacers for the treatment of infection associated with total hip or knee arthroplasty. *J Bone Joint Surg Am* **2007**; 89:871–82.
106. Hanssen AD, Rand JA, Osmon DR. Treatment of the infected total knee arthroplasty with insertion of another prosthesis. The effect of antibiotic-impregnated bone cement. *Clin Orthop Relat Res* **1994**; 44–55.
107. Jiranek WA, Hanssen AD, Greenwald AS. Antibiotic-loaded bone cement for infection prophylaxis in total joint replacement. *J Bone Joint Surg Am* **2006**; 88:2487–500.
108. Mabry TM, Hanssen AD. Articulating antibiotic spacers: a matter of personal preference. *Orthopedics* **2007**; 30:783–5.
109. McKenna PB, O'Shea K, Masterson EL. Two-stage revision of infected hip arthroplasty using a shortened post-operative course of antibiotics. *Arch Orthop Trauma Surg* **2009**; 129:489–94.
110. Rand JA, Bryan RS. Reimplantation for the salvage of an infected total knee arthroplasty. *J Bone Joint Surg Am* **1983**; 65:1081–6.
111. Sanchez-Sotelo J, Berry DJ, Hanssen AD, Cabanela ME. Midterm to long-term followup of staged reimplantation for infected hip arthroplasty. *Clin Orthop Relat Res* **2009**; 467:219–24.
112. Springer BD, Lee GC, Osmon D, Haidukewych GJ, Hanssen AD, Jacofsky DJ. Systemic safety of high-dose antibiotic-loaded cement spacers after resection of an infected total knee arthroplasty. *Clin Orthop Relat Res* **2004**; 47–51.
113. Stockley I, Mockford BJ, Hoad-Reddick A, Norman P. The use of two-stage exchange arthroplasty with depot antibiotics in the absence of long-term antibiotic therapy in infected total hip replacement. *J Bone Joint Surg Br* **2008**; 90:145–8.
114. Toulson C, Walcott-Sapp S, Hur J, et al. Treatment of infected total hip arthroplasty with a 2-stage reimplantation protocol: update on “our institution’s” experience from 1989 to 2003. *J Arthroplasty* **2009**; 24:1051–60.
115. van Raaij TM, Visser LE, Vulto AG, Verhaar JA. Acute renal failure after local gentamicin treatment in an infected total knee arthroplasty. *J Arthroplasty* **2002**; 17:948–50.
116. Pagnano MW, Trousdale RT, Hanssen AD. Outcome after reinfection following reimplantation hip arthroplasty. *Clin Orthop Relat Res* **1997**; 192–204.

117. Bloomfield MR, Klika AK, Barsoum WK. Antibiotic-coated spacers for total hip arthroplasty infection. *Orthopedics* **2010**; 33:649.
118. Sendi P, Rohrbach M, Graber P, Frei R, Ochsner PE, Zimmerli W. *Staphylococcus aureus* small colony variants in prosthetic joint infection. *Clin Infect Dis* **2006**; 43:961–7.
119. Leung F, Richards CJ, Garbuz DS, Masri BA, Duncan CP. Two-stage total hip arthroplasty: how often does it control methicillin-resistant infection? *Clin Orthop Relat Res* **2011**; 469:1009–15.
120. Westrich GH, Walcott-Sapp S, Bornstein LJ, Bostrom MP, Windsor RE, Brause BD. Modern treatment of infected total knee arthroplasty with a 2-stage reimplantation protocol. *J Arthroplasty* **2010**; 25:1015–21, 1021.e1–2.
121. Del Pozo JL, Patel R. Clinical practice. Infection associated with prosthetic joints. *N Engl J Med* **2009**; 361:787–94.
122. Matthews PC, Berendt AR, McNally MA, Byren I. Diagnosis and management of prosthetic joint infection. *BMJ* **2009**; 338:b1773.
123. Muller M, Morawietz L, Hasart O, Strube P, Perka C, Tohtz S. Diagnosis of periprosthetic infection following total hip arthroplasty—evaluation of the diagnostic values of pre- and intraoperative parameters and the associated strategy to preoperatively select patients with a high probability of joint infection. *J Orthop Surg Res* **2008**; 3:31.
124. Ghanem E, Azzam K, Seeley M, Joshi A, Parvizi J. Staged revision for knee arthroplasty infection: what is the role of serologic tests before reimplantation? *Clin Orthop Relat Res* **2009**; 467:1699–705.
125. Shukla SK, Ward JP, Jacofsky MC, Sporer SM, Paprosky WG, Della Valle CJ. Perioperative testing for persistent sepsis following resection arthroplasty of the hip for periprosthetic infection. *J Arthroplasty* **2010**; 25:87–91.
126. Kusuma SK, Ward J, Jacofsky M, Sporer SM, Della Valle CJ. What is the role of serological testing between stages of two-stage reconstruction of the infected prosthetic knee? *Clin Orthop Relat Res* **2011**; 469:1002–8.
127. Mont MA, Waldman BJ, Hungerford DS. Evaluation of preoperative cultures before second-stage reimplantation of a total knee prosthesis complicated by infection. A comparison-group study. *J Bone Joint Surg Am* **2000**; 82-A:1552–7.
128. Hanssen AD, Trousdale RT, Osmon DR. Patient outcome with reinfection following reimplantation for the infected total knee arthroplasty. *Clin Orthop Relat Res* **1995**; 55–67.
129. Maheshwari AV, Gioe TJ, Kalore NV, Cheng EY. Reinfection after prior staged reimplantation for septic total knee arthroplasty: is salvage still possible? *J Arthroplasty* **2010**; 25:92–7.
130. Azzam K, McHale K, Austin M, Purtill JJ, Parvizi J. Outcome of a second two-stage reimplantation for periprosthetic knee infection. *Clin Orthop Relat Res* **2009**; 467:1706–14.
131. Canner GC, Steinberg ME, Heppenstall RB, Balderston R. The infected hip after total hip arthroplasty. *J Bone Joint Surg Am* **1984**; 66:1393–9.
132. Kantor GS, Osterkamp JA, Dorr LD, Fischer D, Perry J, Conaty JP. Resection arthroplasty following infected total hip replacement arthroplasty. *J Arthroplasty* **1986**; 1:83–9.
133. Grauer JD, Amstutz HC, O'Carroll PF, Dorey FJ. Resection arthroplasty of the hip. *J Bone Joint Surg Am* **1989**; 71:669–78.
134. McElwaine JP, Colville J. Excision arthroplasty for infected total hip replacements. *J Bone Joint Surg Br* **1984**; 66:168–71.
135. Bittar ES, Petty W. Girdlestone arthroplasty for infected total hip arthroplasty. *Clin Orthop Relat Res* **1982**; 83–7.
136. Falahee MH, Matthews LS, Kaufer H. Resection arthroplasty as a salvage procedure for a knee with infection after a total arthroplasty. *J Bone Joint Surg Am* **1987**; 69:1013–21.
137. Mabry TM, Jacofsky DJ, Haidukewych GJ, Hanssen AD. Comparison of intramedullary nailing and external fixation knee arthrodesis for the infected knee replacement. *Clin Orthop Relat Res* **2007**; 464:11–5.
138. Rand JA, Bryan RS, Chao EY. Failed total knee arthroplasty treated by arthrodesis of the knee using the Ace-Fischer apparatus. *J Bone Joint Surg Am* **1987**; 69:39–45.
139. Isiklar ZU, Landon GC, Tullos HS. Amputation after failed total knee arthroplasty. *Clin Orthop Relat Res* **1994**; 173–8.
140. Krijnen MR, Wuisman PI. Emergency hemipelvectomy as a result of uncontrolled infection after total hip arthroplasty: two case reports. *J Arthroplasty* **2004**; 19:803–8.
141. Sierra RJ, Trousdale RT, Pagnano MW. Above-the-knee amputation after a total knee replacement: prevalence, etiology, and functional outcome. *J Bone Joint Surg Am* **2003**; 85-A:1000–4.
142. Fedorka CJ, Chen AF, McGarry WM, Parvizi J, Klatt BA. Functional ability after above-the-knee amputation for infected total knee arthroplasty. *Clin Orthop Relat Res* **2011**; 469:1024–32.
143. Blaser J, Vergeres P, Widmer AF, Zimmerli W. In vivo verification of in vitro model of antibiotic treatment of device-related infection. *Antimicrob Agents Chemother* **1995**; 39:1134–9.
144. Rao N, Ziran BH, Hall RA, Santa ER. Successful treatment of chronic bone and joint infections with oral linezolid. *Clin Orthop Relat Res* **2004**; 67–71.
145. Rao N, Hamilton CW. Efficacy and safety of linezolid for gram-positive orthopedic infections: a prospective case series. *Diagn Microbiol Infect Dis* **2007**; 59:173–9.
146. Razonable RR, Osmon DR, Steckelberg JM. Linezolid therapy for orthopedic infections. *Mayo Clin Proc* **2004**; 79:1137–44.
147. Senneville E, Legout L, Valette M, et al. Effectiveness and tolerability of prolonged linezolid treatment for chronic osteomyelitis: a retrospective study. *Clin Ther* **2006**; 28:1155–63.
148. Falagas ME, Siempos II, Papagelopoulos PJ, Vardakas KZ. Linezolid for the treatment of adults with bone and joint infections. *Int J Antimicrob Agents* **2007**; 29:233–9.
149. Soriano A, Gomez J, Gomez L, et al. Efficacy and tolerability of prolonged linezolid therapy in the treatment of orthopedic implant infections. *Eur J Clin Microbiol Infect Dis* **2007**; 26:353–6.
150. Gebhart BC, Barker BC, Markewitz BA. Decreased serum linezolid levels in a critically ill patient receiving concomitant linezolid and rifampin. *Pharmacotherapy* **2007**; 27:476–9.
151. Rippiat F, Bergiers C, Michel C, Dujardin JP, Derue G. Severe bilateral optic neuritis associated with prolonged linezolid therapy. *J Antimicrob Chemother* **2004**; 53:1114–5.
152. Rho JP, Sia IG, Crum BA, Dekutoski MB, Trousdale RT. Linezolid-associated peripheral neuropathy. *Mayo Clin Proc* **2004**; 79:927–30.
153. Thai XC, Bruno-Murtha LA. Bell's palsy associated with linezolid therapy: case report and review of neuropathic adverse events. *Pharmacotherapy* **2006**; 26:1183–9.
154. Taylor JJ, Wilson JW, Estes LL. Linezolid and serotonergic drug interactions: a retrospective survey. *Clin Infect Dis* **2006**; 43:180–7.
155. Rybak M, Lomaestro B, Rotschafer JC, et al. Therapeutic monitoring of vancomycin in adult patients: a consensus review of the American Society of Health System Pharmacists, the Infectious Diseases Society of America, and the Society of Infectious Diseases Pharmacists. *Am J Health Syst Pharm* **2009**; 66:82–98.
156. Senneville E, Legout L, Valette M, et al. Risk factors for anaemia in patients on prolonged linezolid therapy for chronic osteomyelitis: a case-control study. *J Antimicrob Chemother* **2004**; 54:798–802.
157. Baldoni D, Haschke M, Rajacic Z, Zimmerli W, Trampuz A. Linezolid alone or combined with rifampin against methicillin-resistant *Staphylococcus aureus* in experimental foreign-body infection. *Antimicrob Agents Chemother* **2009**; 53:1142–8.
158. John AK, Baldoni D, Haschke M, et al. Efficacy of daptomycin in implant-associated infection due to methicillin-resistant *Staphylococcus aureus*: importance of combination with rifampin. *Antimicrob Agents Chemother* **2009**; 53:2719–24.

159. Rao N, Regalla DM. Uncertain efficacy of daptomycin for prosthetic joint infections: a prospective case series. *Clin Orthop Relat Res* **2006**; 451:34–7.
160. Antony SJ. Combination therapy with daptomycin, vancomycin, and rifampin for recurrent, severe bone and prosthetic joint infections involving methicillin-resistant *Staphylococcus aureus*. *Scand J Infect Dis* **2006**; 38:293–5.
161. Burns CA. Daptomycin-rifampin for a recurrent MRSA joint infection unresponsive to vancomycin-based therapy. *Scand J Infect Dis* **2006**; 38:133–6.
162. Lamp KC, Friedrich LV, Mendez-Vigo L, Russo R. Clinical experience with daptomycin for the treatment of patients with osteomyelitis. *Am J Med* **2007**; 120:S13–20.
163. Marty FM, Yeh WW, Wennersten CB, et al. Emergence of a clinical daptomycin-resistant *Staphylococcus aureus* isolate during treatment of methicillin-resistant *Staphylococcus aureus* bacteremia and osteomyelitis. *J Clin Microbiol* **2006**; 44:595–7.
164. Liu C, Bayer A, Cosgrove SE, et al. Clinical practice guidelines by the Infectious Diseases Society of America for the treatment of methicillin-resistant *Staphylococcus aureus* infections in adults and children. *Clin Infect Dis* **2011**; 52:e18–55.
165. Fowler VG Jr, Boucher HW, Corey GR, et al. Daptomycin versus standard therapy for bacteremia and endocarditis caused by *Staphylococcus aureus*. *N Engl J Med* **2006**; 355:653–65.
166. Martinez-Pastor JC, Munoz-Mahamad E, Vilchez F, et al. Outcome of acute prosthetic joint infections due to gram-negative bacilli treated with open debridement and retention of the prosthesis. *Antimicrob Agents Chemother* **2009**; 53:4772–7.
167. Legout L, Senneville E, Stern R, et al. Treatment of bone and joint infections caused by gram-negative bacilli with a cefepime-fluoroquinolone combination. *Clin Microbiol Infect* **2006**; 12:1030–3.
168. Senneville E, Poissy J, Legout L, et al. Safety of prolonged high-dose levofloxacin therapy for bone infections. *J Chemother* **2007**; 19:688–93.
169. Goulet JA, Pellicci PM, Brause BD, Salvati EM. Prolonged suppression of infection in total hip arthroplasty. *J Arthroplasty* **1988**; 3:109–16.
170. Rao N, Crossett LS, Sinha RK, Le Frock JL. Long-term suppression of infection in total joint arthroplasty. *Clin Orthop Relat Res* **2003**; 55–60.
171. Tsukayama DT, Wicklund B, Gustilo RB. Suppressive antibiotic therapy in chronic prosthetic joint infections. *Orthopedics* **1991**; 14:841–4.
172. Guglielmo BJ, Lubner AD, Paletta D Jr, Jacobs RA. Ceftriaxone therapy for staphylococcal osteomyelitis: a review. *Clin Infect Dis* **2000**; 30:205–7.
173. Wynn M, Dalovisio JR, Tice AD, Jiang X. Evaluation of the efficacy and safety of outpatient parenteral antimicrobial therapy for infections with methicillin-sensitive *Staphylococcus aureus*. *South Med J* **2005**; 98:590–5.
174. Tice AD, Hoaglund PA, Shultz DA. Outcomes of osteomyelitis among patients treated with outpatient parenteral antimicrobial therapy. *Am J Med* **2003**; 114:723–8.
175. Marculescu CE, Berbari EF, Hanssen AD, Steckelberg JM, Osmon DR. Prosthetic joint infection diagnosed postoperatively by intraoperative culture. *Clin Orthop Relat Res* **2005**; 439:38–42.